

Management of venous leg ulcers: Clinical practice guidelines of the Society for Vascular Surgery[®] and the American Venous Forum

Endorsed by the American College of Phlebology and the Union Internationale de Phlébologie

Thomas F. O'Donnell Jr, MD, Marc A. Passman, MD, William A. Marston, MD, William J. Ennis, DO, Michael Dalsing, MD, Robert L. Kistner, MD, Fedor Lurie, MD, PhD, Peter K. Henke, MD, Monika L. Gloviczki, MD, PhD, Bo G. Eklöf, MD, PhD, Julianne Stoughton, MD, Sesadri Raju, MD, Cynthia K. Shortell, MD, Joseph D. Raffetto, MD, Hugo Partsch, MD, Lori C. Pounds, MD, Mary E. Cummings, MD, David L. Gillespie, MD, Robert B. McLafferty, MD, Mohammad Hassan Murad, MD, Thomas W. Wakefield, MD, and Peter Gloviczki, MD

SVS/AVF Joint Clinical Practice Guidelines Committee—Venous Leg Ulcer

Chair:

Thomas F. O'Donnell Jr, MD (Cardiovascular Center, Tufts Medical Center, Boston, Mass)

Vice Chair:

Marc A. Passman, MD (Division of Vascular Surgery and Endovascular Therapy, University of Alabama at Birmingham, Birmingham, Ala; Birmingham Veterans Administration Medical Center, Birmingham, Ala)

Committee Members:

Mary E. Cummings, MD (University of Michigan, Ann Arbor, Mich)

Michael C. Dalsing, MD (Indiana University School of Medicine, IU Health Care System, Indianapolis, Ind)

Bo G. Eklöf, MD, PhD (Lund University, Sweden)

William J. Ennis, DO (University of Illinois Hospital and Health Science, Chicago, Ill)

David L. Gillespie, MD (Department of Vascular Surgery, Cardiovascular Care Center, Southcoast Healthcare Systems, Fall River, Mass; Uniformed Services University of the Health Sciences F. Edward Hebert School of Medicine, Bethesda, Md)

Monika L. Gloviczki, MD, PhD (Gonda Vascular Center, Mayo Clinic, Rochester, Minn)

Peter Gloviczki, MD (Division of Vascular and Endovascular Surgery, Mayo Clinic, Rochester, Minn)

Peter K. Henke, MD (University of Michigan, Ann Arbor, Mich)

Robert L. Kistner, MD (Honolulu, Hawaii)

Fedor Lurie, MD, PhD (Jobst Vascular Institute, Toledo, Ohio)

William A. Marston, MD (University of North Carolina, Chapel Hill, NC)

Robert B. McLafferty, MD (Portland Veterans Administration Medical Center, Portland, Ore; Oregon Health Sciences University, Portland, Ore)

M. Hassan Murad, MD (Division of Preventive Medicine, Mayo Clinic, Rochester, Minn)

Hugo Partsch, MD (Medical University of Vienna, Austria)

Lori C. Pounds, MD (University of Texas Health Science Center, San Antonio, Tex)

Joseph D. Raffetto, MD (Harvard Medical School, Boston Mass; Veterans Administration Boston Healthcare System, Boston Mass; Brigham and Women's Hospital, Boston, Mass)

Sesadri Raju, MD (The Rane Center, Jackson, Miss)

Cynthia K. Shortell, MD (Division of Vascular Surgery, Duke University Medical Center, Durham, NC)

Julianne Stoughton, MD (Division of Vascular and Endovascular Surgery, Massachusetts General Hospital, Boston, Mass)

Thomas W. Wakefield, MD (University of Michigan, Ann Arbor, Mich)

Author conflict of interest: none.

J Vasc Surg 2014;60:3S-59S

0741-5214/\$36.00

Copyright © 2014 by the Society for Vascular Surgery.

<http://dx.doi.org/10.1016/j.jvs.2014.04.049>

Sub-Committee—Clinical Evaluation:

Marc A. Passman, MD (chair); Peter K. Henke, MD; William A. Marston, MD; Robert B. McLafferty, MD; Lori Pounds, MD

Sub-Committee—Wound Care:

William A. Marston, MD (co-Chair); William J. Ennis, DO (co-Chair); Emily Cummings, MD; Thomas F. O'Donnell Jr, MD; Lori C. Pounds, MD

Sub-Committee—Compression:

Fedor Lurie, MD, PhD (co-Chair); Thomas W. Wakefield, MD (co-Chair); MD; Monika L. Gloviczki, MD, PhD; Hugo Partsch, MD; Cynthia Shortell, MD

Sub-Committee—Surgery:

Michael C. Dalsing, MD (co-Chair); Robert Kistner, MD (co-Chair); Bo G. Eklöf, MD, PhD; David Gillespie, MD; Peter Gloviczki, MD; Julianne Stoughton, MD; Sesadri Raju, MD

Sub-Committee—Ancillary:

Monika L. Gloviczki, MD, PhD (Chair); Cynthia K. Shortell, MD; Julianne Stoughton, MD; William J. Ennis, DO

Sub-Committee—Primary Prevention:

Peter K. Henke, MD (Chair); Emily Cummings, MD; Michael C. Dalsing, MD; Fedor Lurie, MD, PhD

Section Contributors

Editors: Thomas F. O'Donnell Jr, MD; Marc A. Passman, MD

Summary of Guidelines: SVS/AVF Committee

Need for Intersociety Consensus Guidelines: Thomas F. O'Donnell Jr, MD

Methodology of Guidelines: Thomas F. O'Donnell Jr, MD; Mohammad Hassan Murad, MD

Definition—Venous Leg Ulcer: Thomas F. O'Donnell Jr, MD; Robert Kistner, MD

Venous Anatomy and Pathophysiology: Marc A. Passman, MD (Anatomy); Joseph D. Raffetto, MD (Pathophysiology)

Clinical Evaluation: Marc A. Passman, MD; William A. Marston, MD; Peter Henke, MD; Robert B. McLafferty, MD; Lori C. Pounds, MD; William J. Ennis, MD

Wound Care: William A. Marston, MD; William J. Ennis, DO; Emily Cummings, MD; Lori Pounds, MD; Thomas F. O'Donnell Jr, MD

Compression: Fedor Lurie, MD, PhD; Thomas W. Wakefield, MD; Monika L. Gloviczki, MD, PhD; Hugo Partsch, MD; Cynthia Shortell, MD; Andrea Obi, MD (University of Michigan, Ann Arbor, Mich)

Surgery: Michael C. Dalsing, MD; Robert Kistner, MD; Bo G. Eklöf, MD, PhD; Peter Gloviczki, MD; Sesadri Raju, MD; Julianne Stoughton, MD; David Gillespie, MD

Ancillary: Monika L. Gloviczki, MD, PhD; Cynthia K. Shortell, MD; Julianne Stoughton, MD; William J. Ennis, MD; William A. Marston, MD

Primary Prevention: Peter Henke, MD; Fedor Lurie, MD, PhD; Emily Cummings, MD; Michael C. Dalsing, MD

SUMMARY OF GUIDELINES FOR MANAGEMENT OF VENOUS ULCER**DEFINITION VENOUS LEG ULCER****Guideline 1.1: Venous Leg Ulcer Definition**

We suggest use of a standard definition of venous ulcer as an open skin lesion of the leg or foot that occurs in an area affected by venous hypertension. [BEST PRACTICE]

VENOUS ANATOMY AND PATHOPHYSIOLOGY**Guideline 2.1: Venous Anatomy Nomenclature**

We recommend use of the International Consensus Committee on Venous Anatomical Terminology for standardized venous anatomy nomenclature. [BEST PRACTICE]

Guideline 2.2: Venous Leg Ulcer Pathophysiology

We recommend a basic practical knowledge of venous physiology and venous leg ulcer pathophysiology for all practitioners caring for venous leg ulcers. [BEST PRACTICE]

CLINICAL EVALUATION

Guideline 3.1: Clinical Evaluation

We recommend that for all patients with suspected leg ulcers fitting the definition of venous leg ulcer, clinical evaluation for evidence of chronic venous disease be performed. [BEST PRACTICE]

Guideline 3.2: Nonvenous Causes of Leg Ulcers

We recommend identification of medical conditions that affect ulcer healing and other nonvenous causes of ulcers. [BEST PRACTICE]

Guideline 3.3: Wound Documentation

We recommend serial venous leg ulcer wound measurement and documentation. [BEST PRACTICE]

Guideline 3.4: Wound Culture

We suggest against routine culture of venous leg ulcers and only to obtain wound culture specimens when clinical evidence of infection is present. [GRADE - 2; LEVEL OF EVIDENCE - C]

Guideline 3.5: Wound Biopsy

We recommend wound biopsy for leg ulcers that do not improve with standard wound and compression therapy after 4 to 6 weeks of treatment and for all ulcers with atypical features. [GRADE - 1; LEVEL OF EVIDENCE - C]

Guideline 3.6: Laboratory Evaluation

We suggest laboratory evaluation for thrombophilia for patients with a history of recurrent venous thrombosis and chronic recurrent venous leg ulcers. [GRADE - 2; LEVEL OF EVIDENCE - C]

Guideline 3.7: Arterial Testing

We recommend arterial pulse examination and measurement of ankle-brachial index on all patients with venous leg ulcer. [GRADE - 1; LEVEL OF EVIDENCE - B]

Guideline 3.8: Microcirculation Assessment

We suggest against routine microcirculation assessment of venous leg ulcers but suggest selective consideration as an adjunctive assessment for monitoring of advanced wound therapy. [GRADE - 2; LEVEL OF EVIDENCE - C]

Guideline 3.9: Venous Duplex Ultrasound

We recommend comprehensive venous duplex ultrasound examination of the lower extremity in all patients with suspected venous leg ulcer. [GRADE - 1; LEVEL OF EVIDENCE - B]

Guideline 3.10: Venous Plethysmography

We suggest selective use of venous plethysmography in the evaluation of patients with suspected venous leg ulcer if venous duplex ultrasound does not provide definitive diagnostic information. [GRADE - 2; LEVEL OF EVIDENCE - B]

Guideline 3.11: Venous Imaging

We suggest selective computed tomography venography, magnetic resonance venography, contrast venography, and/or intravascular ultrasound in patients with suspected venous leg ulceration if additional advanced venous diagnosis is required for thrombotic or nonthrombotic iliac vein obstruction or for operative planning before open or endovenous interventions. [GRADE - 2; LEVEL OF EVIDENCE - C]

Guideline 3.12: Venous Disease Classification

We recommend that all patients with venous leg ulcer be classified on the basis of venous disease classification assessment, including clinical CEAP, revised Venous Clinical Severity Score, and venous disease-specific quality of life assessment. [BEST PRACTICE]

Guideline 3.13: Venous Procedural Outcome Assessment

We recommend venous procedural outcome assessment including reporting of anatomic success, venous hemodynamic success, procedure-related minor and major complications, and impact on venous leg ulcer healing. [BEST PRACTICE]

WOUND CARE

Guideline 4.1: Wound Cleansers

We suggest that venous leg ulcers be cleansed initially and at each dressing change with a neutral, nonirritating, nontoxic solution, performed with a minimum of chemical or mechanical trauma. [GRADE - 2; LEVEL OF EVIDENCE - C]

Guideline 4.2: Débridement

We recommend that venous leg ulcers receive thorough débridement at their initial evaluation to remove obvious necrotic tissue, excessive bacterial burden, and cellular burden of dead and senescent cells. [GRADE - 1; LEVEL OF EVIDENCE - B] We suggest that additional maintenance débridement be performed to maintain the appearance and readiness of the wound bed for healing. [GRADE - 2; LEVEL OF EVIDENCE - B] We suggest that the health care provider choose from a number of débridement methods, including sharp, enzymatic, mechanical, biologic, and autolytic. More than one débridement method may be appropriate. [GRADE - 2; LEVEL OF EVIDENCE - B]

Guideline 4.3: Anesthesia for Surgical Débridement

We recommend that local anesthesia (topical or local injection) be administered to minimize discomfort associated with surgical venous leg ulcer débridement. In selected cases, regional block or general anesthesia may be required. [GRADE - 1; LEVEL OF EVIDENCE - B]

Guideline 4.4: Surgical Débridement

We recommend that surgical débridement be performed for venous leg ulcers with slough, nonviable tissue, or eschar. Serial wound assessment is important in determining the need for repeated débridement. [GRADE - 1; LEVEL OF EVIDENCE - B]

Guideline 4.5 Hydrosurgical Débridement

We suggest hydrosurgical débridement as an alternative to standard surgical débridement of venous leg ulcers. [GRADE - 2; LEVEL OF EVIDENCE - B]

Guideline 4.6: Ultrasonic Débridement

We suggest against ultrasonic débridement over surgical débridement in the treatment of venous leg ulcers. [GRADE - 2; LEVEL OF EVIDENCE - C]

Guideline 4.7: Enzymatic Débridement

We suggest enzymatic débridement of venous leg ulcers when no clinician trained in surgical débridement is available to débride the wound. [GRADE - 2; LEVEL OF EVIDENCE - C] We do not suggest enzymatic débridement over surgical débridement. [GRADE - 2; LEVEL OF EVIDENCE - C]

Guideline 4.8: Biologic Débridement

We suggest that larval therapy for venous leg ulcers can be used as an alternative to surgical débridement. [GRADE - 2; LEVEL OF EVIDENCE - B]

Guideline 4.9: Management of Limb Cellulitis

We recommend that cellulitis (inflammation and infection of the skin and subcutaneous tissue) surrounding the venous leg ulcer be treated with systemic gram-positive antibiotics. [GRADE - 1; LEVEL OF EVIDENCE - B]

Guideline 4.10: Wound Colonization and Bacterial Biofilms

We suggest against systemic antimicrobial treatment of venous leg ulcer colonization or biofilm without clinical evidence of infection. [GRADE - 2; LEVEL OF EVIDENCE - C]

Guideline 4.11: Treatment of Wound Infection

We suggest that venous leg ulcers with $>1 \times 10^6$ CFU/g of tissue and clinical evidence of infection be treated with antimicrobial therapy. [GRADE - 2; LEVEL OF EVIDENCE - C] We suggest antimicrobial therapy for virulent or difficult to eradicate bacteria (such as beta-hemolytic streptococci, pseudomonas, and resistant staphylococcal species) at lower levels of colony-forming units per gram of tissue. [GRADE - 2; LEVEL OF EVIDENCE - C] We suggest a combination of mechanical disruption and antibiotic therapy as most likely to be successful in eradicating venous leg ulcer infection. [GRADE - 2; LEVEL OF EVIDENCE - C]

Guideline 4.12: Systemic Antibiotics

We recommend that venous leg ulcers with clinical evidence of infection be treated with systemic antibiotics guided by sensitivities performed on wound culture. [GRADE - 1; LEVEL OF EVIDENCE - C] Oral antibiotics are preferred initially, and the duration of antibiotic therapy should be limited to 2 weeks unless persistent evidence of wound infection is present. [GRADE - 1; LEVEL OF EVIDENCE - C]

Guideline 4.13: Topical Antibiotics for Infected Wounds

We suggest against use of topical antimicrobial agents for the treatment of infected venous leg ulcers. [GRADE - 2; LEVEL OF EVIDENCE - C]

Guideline 4.14: Topical Dressing Selection

We suggest applying a topical dressing that will manage venous leg ulcer exudate and maintain a moist, warm wound bed. [GRADE - 2; LEVEL OF EVIDENCE - C] We suggest selection of a primary wound dressing that will absorb wound exudate produced by the ulcer (alginates, foams) and protect the periwound skin. [GRADE - 2; LEVEL OF EVIDENCE - B]

Guideline 4.15: Topical Dressings Containing Antimicrobials

We recommend against the routine use of topical antimicrobial-containing dressings in the treatment of noninfected venous leg ulcers. [GRADE - 2; LEVEL OF EVIDENCE - A]

Guideline 4.16: Periwound Skin Management

We suggest application of skin lubricants underneath compression to reduce dermatitis that commonly affects periwound skin. [GRADE - 2; LEVEL OF EVIDENCE - C] In severe cases of dermatitis associated with venous leg ulcers, we suggest topical steroids to reduce the development of secondary ulcerations and to reduce the symptoms of dermatitis. [GRADE - 2; LEVEL OF EVIDENCE - C]

Guideline 4.17: Anti-inflammatory Therapies

We suggest against use of anti-inflammatory therapies for the treatment of venous leg ulcers. [GRADE - 2; LEVEL OF EVIDENCE - C]

Guideline 4.18: Indications for Adjuvant Therapies

We recommend adjuvant wound therapy options for venous leg ulcers that fail to demonstrate improvement after a minimum of 4 to 6 weeks of standard wound therapy. [GRADE - 1; LEVEL OF EVIDENCE - B]

Guideline 4.19: Split-thickness Skin Grafting

We suggest against split-thickness skin grafting as primary therapy in treatment of venous leg ulcers. [GRADE - 2; LEVEL OF EVIDENCE - B] We suggest split-thickness skin grafting with continued compression for selected large venous leg ulcers that have failed to show signs of healing with standard care for 4 to 6 weeks. [GRADE - 2; LEVEL OF EVIDENCE - B]

Guideline 4.20: Cellular Therapy

We suggest the use of cultured allogeneic bilayer skin replacements (with both epidermal and dermal layers) to increase the chances for healing in patients with difficult to heal venous leg ulcers in addition to compression therapy in patients who have failed to show signs of healing after standard therapy for 4 to 6 weeks. [GRADE - 2; LEVEL OF EVIDENCE - A]

Guideline 4.21: Preparation for Cellular Therapy

We suggest a therapeutic trial of appropriate compression and wound bed moisture control before application of cellular therapy. [GRADE - 2; LEVEL OF EVIDENCE - C] We recommend that adequate wound bed preparation, including complete removal of slough, debris, and any necrotic tissue, be completed before the application of a bilayered cellular graft. [GRADE - 1; LEVEL OF EVIDENCE - C] We recommend additional evaluation and management of increased bioburden levels before the application of cellular therapy. [GRADE - 1; LEVEL OF EVIDENCE - C]

Guideline 4.22: Frequency of Cellular Therapy Application

We suggest reapplication of cellular therapy as long as the venous leg ulcer continues to respond on the basis of wound documentation. [GRADE - 2; LEVEL OF EVIDENCE - C]

Guideline 4.23: Tissue Matrices, Human Tissues, or Other Skin Substitutes

We suggest the use of a porcine small intestinal submucosal tissue construct in addition to compression therapy for the treatment of venous leg ulcers that have failed to show signs of healing after standard therapy for 4 to 6 weeks. [GRADE - 2; LEVEL OF EVIDENCE - B]

Guideline 4.24: Negative Pressure Therapy

We suggest against routine primary use of negative pressure wound therapy for venous leg ulcers. [GRADE - 2; LEVEL OF EVIDENCE - C]

Guideline 4.25: Electrical Stimulation

We suggest against electrical stimulation therapy for venous leg ulcers. [GRADE - 2; LEVEL OF EVIDENCE - C]

Guideline 4.26: Ultrasound Therapy

We suggest against routine ultrasound therapy for venous leg ulcers. [GRADE - 2; LEVEL OF EVIDENCE - B]

COMPRESSION

Guideline 5.1: Compression—Ulcer Healing

In a patient with a venous leg ulcer, we recommend compression therapy over no compression therapy to increase venous leg ulcer healing rate. [GRADE - 1; LEVEL OF EVIDENCE - A]

Guideline 5.2: Compression—Ulcer Recurrence

In a patient with a healed venous leg ulcer, we suggest compression therapy to decrease the risk of ulcer recurrence. [GRADE - 2; LEVEL OF EVIDENCE - B]

Guideline 5.3: Multicomponent Compression Bandage

We suggest the use of multicomponent compression bandage over single-component bandages for the treatment of venous leg ulcers. [GRADE - 2; LEVEL OF EVIDENCE - B]

Guideline 5.4: Compression—Arterial Insufficiency

In a patient with a venous leg ulcer and underlying arterial disease, we do not suggest compression bandages or stockings if the ankle-brachial index is 0.5 or less or if absolute ankle pressure is less than 60 mm Hg. [GRADE - 2; LEVEL OF EVIDENCE - C]

Guideline 5.5: Intermittent Pneumatic Compression

We suggest use of intermittent pneumatic compression when other compression options are not available, cannot be used, or have failed to aid in venous leg ulcer healing after prolonged compression therapy. [GRADE - 2; LEVEL OF EVIDENCE - C]

OPERATIVE/ENDOVASCULAR MANAGEMENT**Guideline 6.1: Superficial Venous Reflux and Active Venous Leg Ulcer—Ulcer Healing**

In a patient with a venous leg ulcer (C6) and incompetent superficial veins that have axial reflux directed to the bed of the ulcer, we suggest ablation of the incompetent veins in addition to standard compressive therapy to improve ulcer healing. [GRADE - 2; LEVEL OF EVIDENCE - C]

Guideline 6.2: Superficial Venous Reflux and Active Venous Leg Ulcer—Prevent Recurrence

In a patient with a venous leg ulcer (C6) and incompetent superficial veins that have axial reflux directed to the bed of the ulcer, we recommend ablation of the incompetent veins in addition to standard compressive therapy to prevent recurrence. [GRADE - 1; LEVEL OF EVIDENCE - B]

Guideline 6.3: Superficial Venous Reflux and Healed Venous Leg Ulcer

In a patient with a healed venous leg ulcer (C5) and incompetent superficial veins that have axial reflux directed to the bed of the ulcer, we recommend ablation of the incompetent veins in addition to standard compressive therapy to prevent recurrence. [GRADE - 1; LEVEL OF EVIDENCE - C]

Guideline 6.4: Superficial Venous Reflux With Skin Changes at Risk for Venous Leg Ulcer (C4b)

In a patient with skin changes at risk for venous leg ulcer (C4b) and incompetent superficial veins that have axial reflux directed to the bed of the affected skin, we suggest ablation of the incompetent superficial veins in addition to standard compressive therapy to prevent ulceration. [GRADE - 2; LEVEL OF EVIDENCE - C]

Guideline 6.5: Combined Superficial and Perforator Venous Reflux With or Without Deep Venous Reflux and Active Venous Leg Ulcer

In a patient with a venous leg ulcer (C6) and incompetent superficial veins that have reflux to the ulcer bed in addition to pathologic perforating veins (outward flow of >500 ms duration, with a diameter of >3.5 mm) located beneath or associated with the ulcer bed, we suggest ablation of both the incompetent superficial veins and perforator veins in addition to standard compressive therapy to aid in ulcer healing and to prevent recurrence. [GRADE - 2; LEVEL OF EVIDENCE - C]

Guideline 6.6: Combined Superficial and Perforator Venous Reflux With or Without Deep Venous Disease and Skin Changes at Risk for Venous Leg Ulcer (C4b) or Healed Venous Ulcer (C5)

In a patient with skin changes at risk for venous leg ulcer (C4b) or healed venous ulcer (C5) and incompetent superficial veins that have reflux to the ulcer bed in addition to pathologic perforating veins (outward flow of >500 ms duration, with a diameter of >3.5 mm) located beneath or associated with the healed ulcer bed, we suggest ablation of the incompetent superficial veins to prevent the development or recurrence of a venous leg ulcer. [GRADE - 2; LEVEL OF EVIDENCE - C] Treatment of the incompetent perforating veins can be performed simultaneously with correction of axial reflux or can be staged with re-evaluation of perforator veins for persistent incompetence after correction of axial reflux. [GRADE - 2; LEVEL OF EVIDENCE - C]

Guideline 6.7: Pathologic Perforator Venous Reflux in the Absence of Superficial Venous Disease, With or Without Deep Venous Reflux, and a Healed or Active Venous Ulcer

In a patient with isolated pathologic perforator veins (outward flow of >500 ms duration, with a diameter of >3.5 mm) located beneath or associated with the healed (C5) or active ulcer (C6) bed regardless of the status of the deep veins, we suggest ablation of the “pathologic” perforating veins in addition to standard compression therapy to aid in venous ulcer healing and to prevent recurrence. [GRADE - 2; LEVEL OF EVIDENCE - C]

Guideline 6.8: Treatment Alternatives for Pathologic Perforator Veins

For those patients who would benefit from pathologic perforator vein ablation, we recommend treatment by percutaneous techniques that include ultrasound-guided sclerotherapy or endovenous thermal ablation (radiofrequency or laser) over open venous perforator surgery to eliminate the need for incisions in areas of compromised skin. [GRADE - 1; LEVEL OF EVIDENCE - C]

Guideline 6.9: Infrainguinal Deep Venous Obstruction and Skin Changes at Risk for Venous Leg Ulcer (C4b), Healed (C5) or Active (C6) Venous Leg Ulcer

In a patient with infrainguinal deep venous obstruction and skin changes at risk for venous leg ulcer (C4b), healed venous leg ulcer (C5), or active venous leg ulcer (C6), we suggest autogenous venous bypass or endophlebectomy in addition to standard compression therapy to aid in venous ulcer healing and to prevent recurrence. [GRADE - 2; LEVEL OF EVIDENCE - C]

Guideline 6.10: Deep Venous Reflux With Skin Changes at Risk for Venous Leg Ulcer (C4b), Healed (C5) or Active (C6) Venous Leg Ulcer—Ligation

In a patient with infrainguinal deep venous reflux and skin changes at risk for venous leg ulcer (C4b), healed venous leg ulcer (C5), or active venous leg ulcer (C6), we suggest against deep vein ligation of the femoral or popliteal veins as a routine treatment. [GRADE - 2; LEVEL OF EVIDENCE - C]

Guideline 6.11: Deep Venous Reflux With Skin Changes at Risk for Venous Leg Ulcer (C4b), Healed (C5) or Active (C6) Venous Leg Ulcer—Primary Valve Repair

In a patient with infrainguinal deep venous reflux and skin changes at risk for venous leg ulcer (C4b), healed venous leg ulcer (C5), or active venous leg ulcer (C6), we suggest individual valve repair for those who have axial reflux with structurally preserved deep venous valves in addition to standard compression therapy to aid in venous ulcer healing and to prevent recurrence. [GRADE - 2; LEVEL OF EVIDENCE - C]

Guideline 6.12: Deep Venous Reflux With Skin Changes at Risk for Venous Leg Ulcer (C4b), Healed (C5) or Active (C6) Venous Leg Ulcer—Valve Transposition or Transplantation

In a patient with infrainguinal deep venous reflux and skin changes at risk for venous leg ulcer (C4b), healed venous leg ulcer (C5), or active venous leg ulcer (C6), we suggest valve transposition or transplantation for those with absence of structurally preserved axial deep venous valves when competent outflow venous pathways are anatomically appropriate for surgical anastomosis in addition to standard compression therapy to aid in venous leg ulcer healing and to prevent recurrence. [GRADE - 2; LEVEL OF EVIDENCE - C]

Guideline 6.13: Deep Venous Reflux With Skin Changes at Risk for Venous Leg Ulcer (C4b), Healed (C5) or Active (C6) Venous Leg Ulcer—Autogenous Valve Substitute

In a patient with infrainguinal deep venous reflux and skin changes at risk for venous leg ulcer (C4b), healed venous leg ulcer (C5), or active venous leg ulcer (C6), we suggest consideration of autogenous valve substitutes by surgeons experienced in these techniques to facilitate ulcer healing and to prevent recurrence in those with no other option available in addition to standard compression therapy to aid in venous ulcer healing and to prevent recurrence. [GRADE - 2; LEVEL OF EVIDENCE - C]

Guideline 6.14: Proximal Chronic Total Venous Occlusion/Severe Stenosis With Skin Changes at Risk for Venous Leg Ulcer (C4b), Healed (C5) or Active (C6) Venous Leg Ulcer—Endovascular Repair

In a patient with inferior vena cava or iliac vein chronic total occlusion or severe stenosis, with or without lower extremity deep venous reflux disease, that is associated with skin changes at risk for venous leg ulcer (C4b), healed venous leg ulcer (C5), or active venous leg ulcer (C6), we recommend venous angioplasty and stent recanalization in addition to standard compression therapy to aid in venous ulcer healing and to prevent recurrence. [GRADE - 1; LEVEL OF EVIDENCE - C]

Guideline 6.15: Proximal Chronic Venous Occlusion/Severe Stenosis (Bilateral) With Recalcitrant Venous Ulcer—Open Repair

In a patient with inferior vena cava or iliac vein chronic occlusion or severe stenosis, with or without lower extremity deep venous reflux disease, that is associated with a recalcitrant venous leg ulcer and failed endovascular treatment, we suggest open surgical bypass with use of an externally supported expanded polytetrafluoroethylene graft in addition to standard compression therapy to aid in venous leg ulcer healing and to prevent recurrence. [GRADE - 2; LEVEL OF EVIDENCE - C]

Guideline 6.16: Unilateral Iliofemoral Venous Occlusion/Severe Stenosis With Recalcitrant Venous Ulcer—Open Repair

In a patient with unilateral iliofemoral venous occlusion/severe stenosis with recalcitrant venous leg ulcer for whom attempts at endovascular reconstruction have failed, we suggest open surgical bypass with use of saphenous vein as a cross-pubic bypass (Palma procedure) to aid in venous ulcer healing and to prevent recurrence. A synthetic graft is an alternative in the absence of autogenous tissue. [GRADE - 2; LEVEL OF EVIDENCE - C]

Guideline 6.17: Proximal Chronic Total Venous Occlusion/Severe Stenosis (Bilateral or Unilateral) With Recalcitrant Venous Ulcer—Adjunctive Arteriovenous Fistula

For those patients who would benefit from an open venous bypass, we suggest the addition of an adjunctive arteriovenous fistula (4-6 mm in size) as an adjunct to improve inflow into autologous or prosthetic crossover bypasses when the inflow is judged to be poor to aid in venous leg ulcer healing and to prevent recurrence. [GRADE - 2; LEVEL OF EVIDENCE - C]

ANCILLARY MEASURES**Guideline 7.1: Nutrition Assessment and Management**

We recommend that nutrition assessment be performed in any patient with a venous leg ulcer who has evidence of malnutrition and that nutritional supplementation be provided if malnutrition is identified. [BEST PRACTICE]

Guideline 7.2: Systemic Drug Therapy

For long-standing or large venous leg ulcer, we recommend treatment with either pentoxifylline or micronized purified flavonoid fraction used in combination with compression therapy. [GRADE - 1; LEVEL OF EVIDENCE - B]

Guideline 7.3: Physiotherapy

We suggest supervised active exercise to improve muscle pump function and to reduce pain and edema in patients with venous leg ulcers. [GRADE - 2; LEVEL OF EVIDENCE - B]

Guideline 7.4: Manual Lymphatic Drainage

We suggest against adjunctive lymphatic drainage for healing of the chronic venous leg ulcers. [GRADE - 2; LEVEL OF EVIDENCE - C]

Guideline 7.5: Balneotherapy

We suggest balneotherapy to improve skin trophic changes and quality of life in patients with advanced venous disease. [GRADE - 2; LEVEL OF EVIDENCE - B]

Guideline 7.6: Ultraviolet light

We suggest against use of ultraviolet light for the treatment of venous leg ulcers. [GRADE - 2; LEVEL OF EVIDENCE - C]

PRIMARY PREVENTION**Guideline 8.1: Primary Prevention—Clinical CEAP C3-4 Primary Venous Disease**

In patients with clinical CEAP C3-4 disease due to primary valvular reflux, we recommend compression, 20 to 30 mm Hg, knee or thigh high. [GRADE - 2; LEVEL OF EVIDENCE - C]

Guideline 8.2: Primary Prevention—Clinical CEAP C1-4 Post-thrombotic Venous Disease

In patients with clinical CEAP C1-4 disease related to prior deep venous thrombosis (DVT), we recommend compression, 30 to 40 mm Hg, knee or thigh high. [GRADE - 1; LEVEL OF EVIDENCE - B]

Guideline 8.3: Primary Prevention—Acute DVT Treatment

As post-thrombotic syndrome is a common preceding event for venous leg ulcers, we recommend current evidence-based therapies for acute DVT treatment. [GRADE - 1; LEVEL OF EVIDENCE - B] We suggest use of low-molecular-weight heparin over vitamin K antagonist therapy of 3-month duration to decrease post-thrombotic syndrome. [GRADE - 2; LEVEL OF EVIDENCE - B] We suggest catheter-directed thrombolysis in patients with low bleeding risk with iliofemoral DVT of duration <14 days. [GRADE - 2; LEVEL OF EVIDENCE - B]

Guideline 8.4: Primary Prevention—Education Measures

In patients with C1-4 disease, we suggest patient and family education, regular exercise, leg elevation when at rest, careful skin care, weight control, and appropriately fitting foot wear. [BEST PRACTICE]

Guideline 8.5: Primary Prevention—Operative Therapy

In patients with asymptomatic C1-2 disease from either primary or secondary causes, we suggest against prophylactic interventional therapies to prevent venous leg ulcer. [GRADE - 2; LEVEL OF EVIDENCE - C]

RATIONALE FOR VENOUS LEG ULCER GUIDELINES

Guidelines present a synthesis of evidence-based recommendations for the diagnosis and treatment of a specific medical condition.¹ The value of a guideline is that it provides consistency among treatment protocols given to patients, resulting in improved efficacy and the quality of

care and reduced cost. The need for cost containment of health care has placed the development and implementation of clinical care guidelines as a high priority for health care systems. Both the prevalence of venous leg ulcers (VLUs)—1% to 1.5% of the population—and the economic impact of VLUs are two compelling reasons to develop a specific guideline for this problem.² The care

of VLUs can consume a significant amount of resources, so that an agreed on "best practice" algorithm can maximize the quality and effectiveness of care while minimizing cost and resource use.³ Moreover, VLUs are associated with prolonged disability, important socioeconomic impact, and significant psychosocial morbidity. Because approximately 50% of VLUs may recur within 10 years, they are marked by a significant component of chronicity, which compounds their economic impact and need for repetitive care. VLUs also can be painful, so that a patient's ability to work may be compromised, and can also affect the retired segments of the population, thereby compounding both the indirect and direct costs of treating VLU.

Epidemiology of Venous Leg Ulcers. VLUs are the most common ulceration on the lower extremity and account for 70% of all leg ulcers.⁴ Various estimates have been made from observational studies on the prevalence of VLU, ranging between 0.06% and 2%. The Edinburgh study, which was a cross-sectional study of a random sample of more than 1500 people between the ages of 18 and 64 years, provided an estimate of VLU prevalence of 1%.⁵ This lower prevalence contrasts with the higher prevalence of an earlier study (2.7% clinical CEAP C5/C6), which was based on a questionnaire and photographs of the legs of the participants.⁶ As in the Edinburgh study, VLU prevalence increased with age. Two other studies examined large populations. Approximately 40,000 Polish patients underwent clinical evaluation and interviews by a variety of health care professionals in a multicenter study showing a 1.5% prevalence of C5/C6 disease.⁷ Another cross-sectional study carried out in France addressed a subset of patients from a larger study of Raynaud patients. All of the 400 patients were evaluated by vascular medicine specialists. C5 disease was higher in men (5.4%) than in women (2.7%), but the investigators observed no open ulcers.⁸ The most detailed information comes from the Bonn Vein Longitudinal Study initiated by the German Ministry of Health.⁹ More than 3000 participants were randomly identified between the ages of 18 and 79 years. Advanced chronic venous reflux (chronic venous insufficiency [CVI]) was found in 0.6% with a healed VLU (C5) and in 0.1% with an open VLU for a total of 0.7%. This longitudinal study documented a decrease in advanced CVI (C4-C6), which may be related to a more comprehensive use of diagnostic and therapeutic modalities for CVI. Because of the high prevalence of venous disease, the AVF National Venous Screening Program was established in the United States to increase awareness. The program screened 2234 individuals and identified varicose veins in more than 30% of participants and more advanced venous disease (C4-C6) in more than 10%.¹⁰ It has been estimated that approximately 2.5 million people suffer from CVI in the United States, and of those, about 20% develop venous ulcers.¹¹

Economic Impact. The overall cost of treating VLU approaches 1% of the health care budget of some western European countries; in the United Kingdom, the annual cost is estimated to range from £300 million to £600

million per year.^{12,13} In the United States, \$2.5 billion was expended for the treatment of VLUs in more than 6 million patients.¹⁴ A recent study on the cost of treating VLUs in Germany demonstrated that mean cost averaged €9569 per patient per year, and 92% of this expenditure was related to direct costs.¹⁵ Although the majority of patients with VLUs can be treated on an outpatient basis and are infrequently hospitalized except for complications, the direct cost of treating VLUs in the United States has been estimated to be \$2500 per month per patient.¹⁶ In the ambulatory setting, the direct cost of this care is related to (1) technical (facility) costs and professional reimbursement (physicians); (2) labor costs (nurses and paramedical personnel) for wound care treatments, which are the major driver of costs; and (3) medications as well as specialized wound dressings and compression garments. A key determinant of the costs of treating VLU is the effectiveness of treatment—not only how rapidly the ulcer heals, but also whether the ulcer recurs. For example, a more expensive wound dressing may have an economic advantage for overall care because of more rapid healing of the VLU with less duration of product use and attendant labor costs.

To determine the actual costs of treating VLUs during a 1-year period, a recent study examined a cohort of 84 patients with nonhealing VLUs (CEAP C6) who presented to a wound clinic. All patients were treated in a wound center by five vascular surgeons with a minimum follow-up of 6 months (median, 368 days; 336-483).¹⁷ Actual costs (not charges) were obtained for outpatient and inpatient facility, visiting nurse services, and physician practice group to yield true cost. The proportion and time to complete healing of VLU were determined to calculate time to healing as well as ulcer-free intervals. Cost/ulcer-free days and cost to complete healing for the entire follow-up period were carried out with univariate analysis of factors affecting cost. The mean total cost of treating VLU during this follow-up period was \$15,732. A total of 50 patients (60%) healed their VLU without recurrence in a mean time of 122 days (6-379 days) at a mean cost of \$10,563 (\$430-\$50,967). Significant contributing factors were outpatient facility fees (\$10,332) and visiting nurse services (\$11,365) related to extended treatment of the open VLU. Patients who failed to heal their ulcer during the duration of this study (20%) had a threefold increase in their costs (\$33,907). Those patients who had recurrence of their VLU (N = 17; 20%) during the follow-up period had a total mean cost of \$12,760. Inpatient admission, of which nearly two thirds was for treatment of infections that were resistant to therapy in an outpatient setting, markedly increased costs (\$33,629). By contrast, VLU treated with surgical intervention of the superficial venous system did not significantly increase total cost over that of patients receiving best medical therapy (\$11,960 vs \$12,304) but significantly reduced recurrence rates (34% vs 5%). By contrast, patients treated for outflow obstruction had a twofold increase in total costs (\$24,241 vs \$11,960).

Value of Clinical Practice Guidelines for Venous Leg Ulcer Care. The value of developing and implementing clinical practice guidelines should be to provide quality of care without a dramatic increase in cost. This focus on “best outcomes for the most reasonable health care dollar” has stimulated many organizations, such as the SVS and AVF, to develop and to promote a unified set of guidelines for treatment of chronic diseases, such as VLUs. An evidence-based analysis of treatment options should decrease the variations in care while at the same time ensuring that resources are used in an optimal manner. Specialty societies, as in the current SVS and AVF guideline, develop clinical practice guidelines either by independent review of available studies or by employing evidence from technology assessments and other published guidelines. For the development of comprehensive clinical practice guidelines on VLUs that would be of value to providers and the health care system in general, an expert panel needs to evaluate the efficacy of individual wound care dressings, surgery, or compression products, as demonstrated in randomized controlled trials (RCTs). In addition, large case series and expert opinion are also used as evidence, although of lower quality. The value of these clinical practice guidelines on VLUs is that they sift through the massive amount of data surrounding the management of VLU and provide a consensus on the evidence, thereby streamlining resources.¹⁸

Survey of the Use of Venous Leg Ulcer Guidelines by Various Health Care Systems. Whereas there are obvious advantages to the development and use of guidelines on VLU, implementation can be a challenge. Such “best practices” can be construed as antithetical to the autonomy of clinical practitioners, who make decisions on the basis of individual patients. These factors may prevent total “buy in” by physicians. Moreover, a set of guidelines can be interpreted as instituting the rigid perspectives of policy makers on health care delivery for a specific disease process. To determine the current status of implementation of guidelines or a specific best practices protocol for the management of VLUs, several large health care systems in the United States as well as in Canada and Europe were surveyed.¹⁸ Vascular units in these facilities were queried on whether a specific set of guidelines or protocols was uniformly applied for two conditions: (1) the treatment of VLU and (2) the prevention of a post-thrombotic limb. This survey demonstrated that guidelines for VLU care are infrequently used by a select group of academic health care systems in the United States (20%), but the majority of single-payer systems in Canada and Europe (82%) employed a VLU guideline. By contrast, the use of guidelines for the prevention of the post-thrombotic limb after deep venous thrombosis (DVT) was comparable between the United States and other countries. This low use of VLU guidelines in the United States occurred despite the availability of guidelines developed by various societies. This finding emphasizes the need for both a comprehensive and a well-promoted guideline for VLUs.

Efficacy of Current Guidelines for Venous Leg Ulcer. Whereas there are various treatment protocols for VLUs, they differ in efficacy, quality, and cost. A more

uniform method of treatment that has been agreed on by a panel of experts and based on clinical evidence for efficacy may improve therapeutic effectiveness and possibly reduce cost. Several studies have demonstrated that after the institution of a VLU guideline, there were improvements in both the ulcer healing and recurrence rate and a subsequent reduced resource use with lowering of treatment costs, thereby supporting adoption of VLU guidelines.¹⁸ Olson et al demonstrated that ulcer healing rate was markedly improved in a Veterans Hospital population of 155 patients with VLU if guideline recommendations were followed. During a 5-year period, patients who received dressings that provided a moist wound healing environment and compression for 80% of their visits were more likely to heal than those who did not comply (<80%; relative risk [RR], 2.52; 95% confidence interval [CI], 1.53-4.16).¹⁹ In a combined study population of patients from the United Kingdom and the United States, patients who were treated for VLUs by a treatment protocol had a 2 times and a 6.5 times greater likelihood of ulcer healing if the guidelines were followed ($P < .01$). Moreover, the median costs were reduced with adherence to VLU guidelines ($P < .01$).²⁰ Finally, in a longitudinal cross-sectional Swedish study of patients in Skaraborg County (population 254,111), the epidemiology of leg ulcers and of VLUs in particular was defined in 1988 before the implementation of a VLU treatment protocol.²¹ The initial point prevalence (proportion with an ulcer at any point of time, time period usually shorter than 3 months) for open VLUs was 0.16% and overall (C5 and C6) was 0.5%. Their protocol for VLU management emphasized early Doppler-aided diagnosis, organized care pathways, and especially surgery for superficial venous incompetence. The effectiveness of the VLU guidelines was judged by the reduction in the point prevalence of VLUs from 1990 to 2005. The institution of guidelines and concomitant implementation of county-wide care plans, based on these guidelines, resulted in a relative risk for VLU of 46%.²²

Objective of SVS and AVF Clinical Practice Guidelines for Venous Leg Ulcer Management. In 2011, SVS and AVF produced clinical practice guidelines for the care of patients with varicose veins and associated venous disease.²³ Although there were some elements of VLU care within this document, most of the emphasis of this guideline was on varicose vein management. In 2012, SVS and AVF clinical practice guidelines addressing early thrombus removal strategies for acute venous thrombosis were published.²⁴ Again, whereas there is some crossover regarding the impact of early venous thrombosis on restored venous patency, potential preserved valvular function, and decreased post-thrombotic morbidity, there was little direct attention on VLUs. The objective of the current SVS and AVF clinical practice guidelines is to focus on complete management of VLUs at all levels of care based on strength and quality of supporting evidence to guide specific recommendations. Combined with these other SVS and AVF clinical practice guidelines, a more complete evidence-based strategy is available for management of patients with chronic venous disease.

METHODOLOGY OF VENOUS LEG ULCER GUIDELINES

The Institute of Medicine, in *Clinical Practice Guidelines We Can Trust*, has defined clinical practice guidelines as “systematically developed statements to assist the practitioner and patient decisions about appropriate healthcare for specific clinical circumstances.”²⁵ The underlying principle is to use evidence-based medicine to the greatest extent to develop these guidelines so that the assessment of the optimal treatment plan is based on the best current available knowledge. Evidence-based medicine allows one to assess the statistical strength of a treatment or intervention and, most important, reduces bias in evaluating a particular therapy.²⁶ Bias is defined as the predisposition of prejudice toward either the experimental or control group, which can lead to either an overestimation or an underestimation of the true benefits and harm of the intervention.²⁷ This method reduces uncertainty, which is the largest single cause of misinterpretation of data.²⁸ This process has been further stated in the recent Institute of Medicine document: “Hence, critically appraised and synthesized scientific evidence has become fundamental to clinical practice. At the same time, and particularly under conditions of uncertainty regarding optimal decisions, clinician experiential knowledge and skill (the “art of medicine”) and patient values and preferences remain essential contributors to quality healthcare practice, in a complex interplay with science.”²⁵

The Venous Ulcer Guidelines Committee was organized through cooperation between the SVS and AVF. The Venous Ulcer Guidelines Committee was divided into six sub-committee sections each headed by a chair: *diagnosis; compression; surgery/endovascular; wound care; ancillary; and prevention*. The overall committee then developed a series of key clinical questions to guide the overall approach for the guideline document: (1) What is the best treatment for active (CEAP C6) venous ulcer? (2) What is the best treatment for healed venous ulcer (CEAP C5)? (3) What is the best method for preventing recurrence of venous ulcers? and (4) Can progression from CEAP C4 to CEAP C6/C5 be prevented? The Venous Ulcer Guidelines Committee addressed the optimal approach to be used for their specific section from four general approaches: (1) de novo development, in which a completely novel recommendation is developed from a systematic and meta-analysis review of the literature; (2) build on existing guidelines with a complementary full-literature search update; (3) adapt guidelines from existing guidelines; and (4) total adoption of existing guidelines.¹⁸ The need for a systematic and meta-analysis review was determined by each section team and then agreed on by the entire committee. Each section was categorized by the type of guideline development required. All guidelines were developed by building on existing guidelines with a complementary literature search by the section sub-committee.

In this process of guideline development for VLUs, the Venous Ulcer Guidelines Committee also reviewed prior

published consensus documents and the AVF report from the 2006 Venous Summit and the 2009 Pacific Vascular Symposium, whose purpose was to reduce the incidence of venous ulcer during the next decade by 50%.²⁹ In a previous systematic review of recently published venous ulcer guidelines, 14 venous ulcer guidelines were identified worldwide.¹⁸ This review showed that there was a high degree of agreement among the 14 VLU guidelines on recommendations for compression (72%), dressings (72%), pentoxifylline (73%), prevention of recurrence by below-knee stockings (70%), and surgery (82%). There was a low proportion of agreement in the areas of diagnosis, clinical evaluation, and venous Doppler and duplex ultrasound; in elements of wound care: measurement of the wound, washing of the wound, débridement, and specific type of wound dressing; and finally in adjunctive measures: the use of skin grafts and physical therapy to promote ankle mobility with enhancement of the calf muscle pump. Several areas of “controversy” were identified that had not been particularly addressed in previous guidelines: new innovative, less invasive VLU therapies; the role of iliac obstruction and occlusion with the need for diagnosis by intravascular ultrasound and subsequent monitoring of stenting by this technique; when and by what methods to treat perforators; the need for physical therapy to promote ankle mobility and function of the calf muscle pump; the role of advanced dressings; and preventing progression to VLU. These areas received special attention in review for the current guidelines.

The *surgery/endovascular* and *compression* sections were selected for a de novo development of specific guideline recommendations based on several of these key questions. For additional systematic review involving these critical areas, the Venous Ulcer Guidelines Committee commissioned an independent group of researchers to conduct two systematic reviews to evaluate the effectiveness of different compression strategies and endovascular and open surgical approaches. The Committee helped develop a priori the protocols of these reviews in terms of outcome selection and criteria for including studies with additional analysis by the Knowledge and Evaluations Research Unit at the Mayo Clinic (Rochester, Minn).^{30,31}

In the literature review, several processes were used to minimize heterogeneity:

- *Language*—all would be included.
- *Type of Studies Reviewed*—randomized controlled trials, controlled clinical trials with cohort, and retrospective large observational case series. The studies should be published in peer-reviewed journals.
- *Target Audience*—this Guideline document is intended for specialists who treat vascular disease and wounds.

Through an iterative process, the committee developed guidelines based on the grading of recommendation assessment, development, and evaluation (GRADE) system (Table I).^{32,33} The strength of the recommendations is

Table I. GRADE recommendations based on level of evidence

<i>Grade</i>	<i>Description of recommendation</i>	<i>Benefit vs risk</i>	<i>Methodologic quality of supporting evidence</i>	<i>Implications</i>
1A	Strong recommendation, high-quality evidence	Benefits clearly outweigh risk and burdens, or vice versa	RCTs without important limitations or overwhelming evidence from observational studies	Strong recommendation, can apply to most patients in most circumstances without reservation
1B	Strong recommendation, moderate-quality evidence	Benefits clearly outweigh risk and burdens, or vice versa	RCTs with important limitations (inconsistent results, methodologic flaws, indirect, or imprecise) or exceptionally strong evidence from observational studies	Strong recommendation, can apply to most patients in most circumstances without reservation
1C	Strong recommendation, low-quality or very-low-quality evidence	Benefits clearly outweigh risk and burdens, or vice versa	Observational studies or case series	Strong recommendation but may change when higher quality evidence becomes available
2A	Weak recommendation, high-quality evidence	Benefits closely balanced with risks and burdens	RCTs without important limitations or overwhelming evidence from observational studies	Weak recommendation, best action may differ depending on circumstances or patients' or societal values
2B	Weak recommendation, moderate-quality evidence	Benefits closely balanced with risks and burdens	RCTs with important limitations (inconsistent results, methodologic flaws, indirect, or imprecise) or exceptionally strong evidence from observational studies	Weak recommendation, best action may differ depending on circumstances or patients' or societal values
2C	Weak recommendation, low-quality or very-low-quality evidence	Uncertainty in the estimates of benefits and risk, and burdens; Risk, benefit, and burdens may be closely balanced	Observational studies or case series	Very weak recommendations; Other alternatives may be reasonable

RCTs, Randomized controlled trials.

Modified from Guyatt G, Gutterman D, Baumann MH, Addrizzo-Harris D, Hylek EM, Phillips B, et al. Grading strength of recommendations and quality of evidence in clinical guidelines: Report from an American College of Chest Physicians task force. *Chest* 2006;129:174-81.

related to (1) the quality of evidence around that recommendation, (2) harm/benefit ratio of the therapy (eg, minimally invasive intervention with few morbid events and a possible effect), and (3) patient preference. Every effort has been made by the committee to make the process of assigning the strength of the particular recommendation as transparent as possible. By the GRADE system, the strength of the recommendation or the extent to which one can be confident that adherence to the recommendation will do more good than harm was divided into [1] strong (we recommend) and [2] weak (we suggest), with [1] favoring benefit over harm and [2] with benefits closely balanced by the risk. The "quality of evidence" or the extent to which confidence in an estimate of effect is sufficient to support a particular recommendation was graded [A], [B], or [C] by standard evidence-based methodologic criteria. It is well recognized that there may not be studies of the highest evidentiary value for the diagnosis and management of VLU. When there are no comparable alternatives to a recommendation or evidence is lacking, the Venous Ulcer Guidelines Committee has relied on case series supplemented by the best opinion of a panel of experts, and the recommendation was labeled [BEST

PRACTICE]. Such recommendations are not graded but deemed by the guideline developers to be necessary to provide a comprehensive guideline that encompasses all the details needed for providing care for patients with venous ulcers.³⁴ In each section and in the comments to each specific recommendation, we have attempted to clearly link the recommendation to the evidence and its quality and to point out where consensus techniques have been used. Independent review of GRADE assignments made by the Venous Ulcer Guidelines Committee was also performed by the Knowledge and Evaluations Research Unit at the Mayo Clinic (Rochester, Minn) to corroborate proper strength of evidence and quality of evidence for each guideline.

The final document was reviewed by the chairman and vice chairman of the Venous Ulcer Guidelines Committee and remitted to the entire committee for concurrence. Additional independent review was obtained from selected reviewers representing multiple medical specialties vested in venous ulcer management. The final document was then reviewed and approved by the SVS Document Oversight Committee and approved by the Executive Committees of the SVS and AVF.

DEFINITION—VENOUS LEG ULCER

Guideline 1.1: Venous Leg Ulcer Definition

We suggest use of a standard definition of venous ulcer as an open skin lesion of the leg or foot that occurs in an area affected by venous hypertension. [BEST PRACTICE]

Inherent in composing a set of guidelines for VLU is agreeing on a common definition of VLU. Current definitions for VLU vary, as exemplified by the following:

- **THE AVF CONSENSUS STATEMENT:** *Venous ulcer is defined as a full-thickness defect of skin, most frequently in ankle region, that fails to heal spontaneously and is sustained by CVD (duplex studies).*³⁵

- **SCOTTISH GUIDELINE DEFINITION:** *Chronic venous leg ulcer is defined as an open lesion between the knee and the ankle joint that remains unhealed for at least four weeks and occurs in the presence of venous disease. Studies reviewed in this guideline included patients with venous leg ulcers, irrespective of the method of diagnosis of venous reflux.*³⁶

- **FRENCH HEALTHCARE SYSTEM GUIDELINES:** *A pure venous ulcer is defined, by professional agreement, as a leg lesion, which has not healed within a month (except in cases of recurrent ulcers when a diagnosis can be made in less than a month); with a pathophysiology due to ambulatory venous hypertension, which may be secondary to: reflux in superficial, perforating or deep veins, and/or obstruction of the deep veins, and/or calf muscle pump dysfunction; where there is no arterial involvement.*³⁷

For the purpose of this Guideline document, we recommend the following definition of VLU: **A venous ulcer is an open skin lesion of the leg or foot that occurs in an area affected by venous hypertension.** Venous hypertension is the result of reflux or obstruction. This may occur as a focal phenomenon in the distal extremity or as a central mechanism, as in ilio caval obstruction or elevated inferior vena cava pressure from advanced truncal obesity. The mere existence of either reflux or obstruction does not appear to be the full cause of venous ulcers, with additional biochemical factors due to activation of the inflammatory cascade, which may act as the inciting factor for appearance of the actual ulcer. Identification of these additional factors awaits further advances in the basic sciences.

At the clinical level, venous ulcers occur as “pure” venous causes, when there is directed axial great saphenous vein reflux or incompetent perforator reflux directly into the ulcer bed, or as “mixed” venous plus other causes, as in cases in which arterial ischemia, scarred tissue of the gaiter area, hypersensitive skin, lymphedema, autoimmune disease, local trauma, infection, and other processes coexist with the venous hypertension. The

mixed ulcers often have a different rate of healing and require additional treatment beyond the appropriate venous measures for healing to occur and recurrence to be prevented. The importance of these diagnoses is that analysis of healing times and effectiveness of surgical treatment of the venous component requires separation of pure venous from mixed ulcers to learn whether treatment of the venous component contributes to faster ulcer healing and early intervention is favored over delayed treatment.

VENOUS ANATOMY AND PATHOPHYSIOLOGY

Guideline 2.1: Venous Anatomy Nomenclature

We recommend use of the International Consensus Committee on Venous Anatomical Terminology for standardized venous anatomy nomenclature. [BEST PRACTICE]

The deep veins of the lower limbs are located in the deep compartment of the leg bound by the muscle fascia and accompany the main arteries of the leg and pelvis. Superficial veins of the lower limbs are those located between the deep fascia covering the muscles of the limb and the skin and primarily included the saphenous system. Perforating veins pass through the deep muscle fascia and connect the superficial to the deep venous system. Communicating veins connect veins within the same system.

Whereas there is general agreement that veins of the lower extremities be divided into superficial, deep, and perforating venous systems, there have been deficiencies in the past in nomenclature for specific veins in the leg within each system. In response to variability in anatomic terminology used for venous anatomy, standard anatomic venous terminology has been developed and adopted. For practitioners caring for patients with VLUs, correct standardized venous nomenclature should be used as defined by the 2002 International Consensus Committee on Venous Anatomical Terminology and updated in 2005 as shown in [Table II](#) and [Table III](#).^{38,39}

Guideline 2.2: Venous Leg Ulcer Pathophysiology

We recommend a basic practical knowledge of venous physiology and venous leg ulcer pathophysiology for all practitioners caring for venous leg ulcers. [BEST PRACTICE]

Chronic venous disease (CVD) is a debilitating condition that affects millions of individuals worldwide. The condition can result in varicose veins or advance to severe skin changes and VLU. Both reflux and obstruction account for the pathophysiologic mechanism of CVD;

Table II. The International Consensus Committee on Venous Anatomical Terminology for standardized venous anatomy nomenclature of the leg

<i>Superficial venous system</i>	<i>Deep venous system</i>	<i>Perforating venous system</i>
Superficial inguinal veins	Common femoral vein	Gluteal perforators
External pudendal vein	Femoral vein	Superior gluteal
Superficial circumflex iliac vein	Deep femoral vein	Midgluteal
Superficial epigastric vein	Medial circumflex femoral vein	Lower gluteal
Superficial dorsal vein (clitoris/penis)	Lateral circumflex femoral vein	Thigh perforators
Anterior labial veins	Deep femoral communicating veins	Medial thigh
Anterior scrotal veins	Sciatic vein	Femoral canal
Great saphenous vein	Popliteal vein	Inguinal
Saphenofemoral junction	Genicular venous plexus	Anterior thigh
Terminal valve	Anterior tibial veins	Lateral thigh
Preterminal valve	Posterior tibial veins	Posterior thigh
Anterior accessory great saphenous vein	Fibular or peroneal veins	Posteromedial
Posterior accessory great saphenous vein	Sural veins	Sciatic
Superficial accessory great saphenous vein	Soleal veins	Posterolateral
Anterior thigh circumflex vein	Gastrocnemius veins	Pudendal
Posterior thigh circumflex vein	Medial	Knee perforators
Small saphenous vein	Lateral	Medial knee
Saphenopopliteal junction	Intergemellar	Suprapatellar
Terminal valve	Medial plantar veins	Lateral knee
Preterminal valve	Lateral plantar veins	Infrapatellar
Cranial extension of small saphenous vein	Deep plantar venous arch	Popliteal fossa
Superficial accessory small saphenous vein	Deep metatarsal veins (plantar/dorsal)	Leg (calf) perforators
Intersaphenous veins	Deep digital veins (plantar/dorsal)	Medial leg
Lateral venous system	Pedal vein	Paratibial
Dorsal venous network of the foot		Posterior tibial
Dorsal venous arch of the foot		Anterior leg
Superficial metatarsal veins (dorsal/plantar)		Lateral leg
Plantar venous subcutaneous network		Posterior leg
Superficial digital veins (dorsal/plantar)		Medial gastrocnemius
Lateral marginal vein		Lateral gastrocnemius
Medial marginal vein		Intergemellar
		Para-achillean
		Ankle perforators
		Medial ankle
		Anterior ankle
		Lateral ankle
		Foot perforators
		Dorsal foot
		Medial foot
		Lateral foot
		Plantar foot

Modified from Caggiati A, Bergan JJ, Gloviczki P, Eklof B, Allegra C, Partsch H. Nomenclature of the veins of the lower limb: Extensions, refinements, and clinical application *J Vasc Surg* 2005;41:719-24.

however, reflux from primary venous disease has a much higher prevalence in patients presenting with the different stages of CVD, which might also include venous ulcers. However, obstruction from secondary venous disease and valvular reflux are associated with a much more rapid progression of disease and a higher rate of progression to venous ulceration.⁴⁰⁻⁴⁴ Whether reflux or obstruction is the cause of the patient's clinical presentation and symptoms is unclear; both conditions lead to increased ambulatory venous pressure. The fundamental basis for CVD and venous ulceration is inflammation within the venous circulation that is subjected to increased hydrostatic pressure resulting in increased ambulatory venous pressure.⁴⁵ The inflammation involves leukocytes (in particular

macrophages and monocytes), inflammatory modulators and chemokines, cytokine expression, growth factors, metalloproteinase activity, and many regulatory pathways that perpetuate inflammation.⁴⁶⁻⁴⁸

The pathophysiologic process of primary venous disease is a complex entity with multifaceted stages leading to the dilated tortuous, valve-insufficient varicose veins, venous hypertension, and the associated clinical manifestations seen with CVD. The pathophysiologic mechanism of secondary venous disease involves inflammation, thrombosis, recanalization resulting in venous wall damage and dilation, and valve insufficiency. The clinical picture is that of the post-thrombotic syndrome (PTS) and can comprise pain,

Table III. The International Consensus Committee on Venous Anatomical Terminology for standardized venous anatomy nomenclature of the pelvis

<i>Main collector</i>	<i>Draining veins</i>	<i>Plexus and peripheral veins</i>
Inferior vena cava	Ovarian/testicular veins	Pampiniform plexus
Common iliac vein	Median sacral vein Iliolumbar vein Internal iliac (hypogastric) External iliac	Sacral venous plexus
Inferior mesenteric vein	Superior rectal vein Middle rectal vein Inferior rectal vein Superior gluteal vein Inferior gluteal vein Lateral sacral vein	External rectal plexus Internal rectal plexus
Internal iliac vein	Internal pudendal vein Obturator veins Vesical veins Uterine veins Vaginal veins	Deep perineal veins Superficial perineal veins Deep dorsal veins of clitoris/penis Deep veins of clitoris/penis Urethral bulb veins Pudendal plexus Vesical/prostatic plexus Uterine plexus Vein of the broad ligament Vaginal plexus
External iliac vein	Pubic veins (accessory obturator veins) Sovrapubic veins Inferior epigastric vein Deep circumflex iliac vein	

Modified from Caggiati A, Bergan JJ, Glowiczki P, Eklof B, Allegra C, Partsch H. Nomenclature of the veins of the lower limb: Extensions, refinements, and clinical application *J Vasc Surg* 2005;41:719-24.

edema, skin changes, and VLU. Failure for recanalization is a risk for development of PTS. When the mean lysis time was reduced, the risk of reflux was significantly reduced, especially in the femoral, popliteal, and deep femoral veins, a critical parameter for preserving valve function.⁴⁹ From a basic science perspective, venous thrombosis and resolution involve important factors including microparticles, P-selectin, coagulation cascade and fibrin, macrophages, adhesion molecules, vascular endothelial growth factor, matrix metalloproteinases (MMPs), inflammatory cytokines and interleukins, chemokines, plasmin, and plasminogen activators and inhibitors, all of which affect the vein wall and its compliance, including valvular function.^{50,51}

Several epidemiologic studies have assessed the associated risk factors. Certainly, genetic and environmental factors influence the predisposition to and perpetuation of primary venous disease. Some important observations

are a family history, female gender, pregnancy, estrogen, prolonged standing, sitting postures, and obesity. Genetic conditions, such as Klippel-Trénaunay syndrome, cerebral autosomal dominant arteriopathy with subcortical infarcts and leukoencephalopathy (CADASIL) and *FOXC2* gene mutations, desmulin dysregulation, and Ehlers-Danlos syndrome, display early onset of varicose veins.^{46,52} However, most individuals with primary venous disease do not have these genetic conditions, and a specific gene leading to primary venous disease and varicose veins has not been identified, although it appears that the trait is autosomal dominant with variable penetrance.^{52,53} Further studies have focused on genetic polymorphism in populations with CVD in the development and healing potential of venous ulcers.⁵⁴ Hemochromatosis C282Y (HFE) gene mutation and certain factor XIII V34L gene variants have been demonstrated in patients with CVD and varicose veins and may have long-term implications for increased risk of the more severe forms of CVD as well as the size of venous ulcers.^{55,56} Factor XIII is an important cross-linking protein that plays a key role during ulcer healing.⁵⁷ HFE and factor XIII genes were also evaluated in predicting VLU healing after superficial venous surgery in patients with CVD. It was demonstrated that specific factor XIII genotypes had favorable ulcer healing rates, whereas the HFE gene mutation, despite its importance in venous ulcer risk, had no influence on healing time.⁵⁸

It is clear from biochemical, immunohistochemical, and functional studies that both the vein wall and the valve are involved in the primary events leading to venous disease. Whether the vein wall changes precede valve insufficiency or the valve insufficiency causes wall distention and wall changes is less clear.⁴⁶ More important, evidence demonstrates that both vein wall and vein valve are pathologically altered to cause primary venous disease. The perturbation in the microcirculation is a critical component in the pathophysiologic process of CVD. The endothelium is a key regulator of vascular tone, hemostasis, and coagulation. Injury, infection, immune diseases, diabetes, genetic predisposition, environmental factors, smoking, and atherosclerosis all have an adverse effect on the endothelium, which in turn must compensate to prevent further injury and maintain integrity of the vascular wall. In CVD, the sine qua non is persistent elevated ambulatory venous pressure. The effect on the microcirculation begins with altered shear stress on the endothelial cells, causing endothelial cells to release vasoactive agents and to express E-selectin, inflammatory molecules, chemokines, and prothrombotic precursors.^{59,60} Mechanical forces, low shear stress, and stretch are sensed by the endothelial cells through intercellular adhesion molecule 1 (ICAM-1, CD54) and the mechanosensitive transient receptor potential vanilloid channels that are present in the endothelium.^{60,61} It is well known that patients with CVD have increased expression of ICAM-1, which is expressed on endothelial cells and

activates the recruitment of leukocytes and initiates endothelial transmigration, setting up an inflammatory cascade.^{62,63} Initiating events likely involve altered shear stress and mechanical stress forces on the endothelium and its glycocalyx (a glycosaminoglycan on the surface of endothelial cells); perturbations in nitric oxide production, in vasoactive substance release, and in the expression of monocyte chemoattractant protein 1, macrophage inflammatory protein 1 β , vascular cell adhesion molecule 1 (VCAM-1, CD106), L-selectins and E-selectins, and ICAM-1, with recruitment of leukocytes leading to leukocyte transmigration into the vein wall and valve, set up an inflammatory cascade and production of several cytokines (transforming growth factor [TGF]- β 1, tumor necrosis factor [TNF]- α , interleukin-1) and increased expression of MMPs.^{48,60} In addition, the endothelial glycocalyx is an important structure that prevents leukocyte adhesion, inflammation, and thrombosis. However, altered shear stress and mechanical forces on the vein wall cause leukocyte adhesion, and inflammation leads to injury and loss of the glycocalyx.^{64,65} A key component of inflammation and in the VLU is the expression of MMP and cytokines, which have significant effects on the vein wall and venous valve, the endothelium, and probably the glycocalyx and surrounding tissues, including destruction of the dermis with eventual skin changes and ulcer formation.⁴⁸ MMPs can be released as a result of mechanical stretch (and hence during conditions of venous hypertension) and have significant effects on the endothelium, venous smooth muscle, and adventitia.^{66,67} MMPs have been demonstrated in rat venous tissue to cause venous dilation by several mechanisms, including hyperpolarization and inhibition of extracellular calcium mobilization, which are tightly regulated by hypoxia-inducible factor (HIF).⁶⁸⁻⁷⁰ In a study evaluating varicose veins in CVD patients, it was determined that HIF-1 α and HIF-2 α transcriptional factors were overexpressed compared with control nonvaricose veins, suggesting that the HIF pathway may be associated with several pathophysiologic changes in the venous wall leading to venous hypertension and that hypoxia may be a feature contributing to the pathogenesis of varicose veins.⁷⁰

MMPs have been found to be present in high quantities in VLUs and the associated wound fluid, and there is a correlation of increased expression of proteinase activity with poor healing. The regulation of MMP production and function, although not fully understood, is likely to be linked to cytokines, urokinase plasminogen activator, EMMPRIN (extracellular MMP inducer CD147), platelet-derived growth factor AA, and mitogen-activated protein kinase pathways.⁷¹⁻⁸² Importantly, the mitogen-activated protein kinase pathways in venous ulcer fibroblast have been demonstrated to overexpress P38, a negative modulator of cell proliferation causing growth arrest, which can also be upregulated with the cytokines TNF- α and interleukin-1. The expression of P38 can be suppressed, leading to fibroblast

growth, by treatment with fibroblast growth factor.^{48,62} Cytokines have important roles at different stages of CVD, beginning with inflammation, with expression in the interstitial space and in the venous ulcer wound bed.⁴⁸ In a nonrandomized evaluation of various cytokine levels and venous ulcer healing in patients undergoing compression therapy, it was determined that untreated ulcers typically display high levels of proinflammatory cytokines, including several interleukins, TNF- α , and interferon- γ . After 4 weeks of compression therapy, the levels of proinflammatory cytokines decreased significantly and the wounds began to heal. After compression, levels of TGF- β 1 increased significantly as the ulcers improved. When specific cytokine levels were related to the percentage of healing, it was found that those with higher levels of proinflammatory cytokines including interleukin-1 and interferon- γ healed significantly better than those with lower levels of these cytokines before compression.⁸³ As a result of venous hypertension, inflammation, and remodeling, a key feature takes place in the postcapillary venule where the fibrin cuff, a complex process involving fibrin and collagen deposition, is formed. The result is a major abnormality in dermal microcirculation with many components forming the postcapillary cuff, including collagen I and III, fibronectin, vitronectin, laminin, tenascin, fibrin, TGF- β 1, and α ₂-macroglobulin.^{48,84} Although the exact mechanisms and reasons for development of the fibrin cuff are unknown, the chemical and structural changes in the postcapillary venule are thought to be in response to changes in shear stress and elevated venous pressures, which probably lead to progressive dermal changes and ulceration. Structural proteins have been analyzed in varicose veins from patients with CVD, with the important finding that overall collagen is increased and both elastin and laminin are decreased.⁸⁵ When the collagen was examined in smooth muscle from varicose veins, the consistent finding was that there was a significant decrease of collagen type III and increased type I, and the same biochemical profile was also observed in the dermal fibroblasts from varicose vein patients.^{85,86} These findings indicate a systemic condition with strong genetic influences, and because collagen I confers rigidity whereas collagen III is involved in the extensibility of a tissue, modification of the collagen I/III ratio might contribute to the weakness and the decreased elasticity of varicose veins. Interestingly, the transcription of collagen III is normal in smooth muscle cells from varicose veins and the activity of MMP-3 is increased, leading to post-translational modification of collagen type III; these events are reversible when MMP-3 is inhibited in vitro.⁸⁷ MMPs are an important step in the development of primary venous disease; their implications are in early events affecting endothelium-smooth muscle interactions and venodilation as well as in late events, with extracellular matrix degradation, structural vein wall changes and fibrosis, and tissue damage leading to venous ulceration.

Venous microvalves have recently been identified both in control specimens and in patients with CVD.⁸⁸ The interesting aspect of that study is a system of sequentially smaller generations of tributaries leading to small venous networks, with competent and incompetent microvalves. The regions are divided into six generations before reaching the small venous network. In regions where incompetence existed in microvalves out to the third-generation tributary (the boundary), the resin (resin injected by retrograde corrosion casting) was able to penetrate deeper into the microvenous networks of the dermis. In limbs with varicose veins and venous ulcers, reflux into the small venous networks and capillary loops was more extensive with more dense networks and greater tortuosity. In addition to superficial axial saphenous vein insufficiency, microvalve insufficiency also existed, and once it compromised the third-generation set of microvalves, there was a greater risk for the development of dermal venous ulceration. These findings may help explain why some patients with long-standing varicose veins do not develop venous ulcers because the microvalves may be intact at the third-generation network, preventing clinical deterioration. In addition, these findings may explain why skin changes consistent with venous disease (hyperpigmentation and even small skin ulceration) are seen clinically in patients with normal findings on duplex ultrasound of the superficial, deep, and perforator venous systems. Further research on the factors responsible for initiating the altered shear stress and stretch on vein walls will make it possible to have specific pharmaceutical targets to restore the integrity of the microcirculation, to treat the spectrum of CVD, and to prevent progression of VLUs.

Metabolic abnormalities may be critical to venous dysfunction and lead to disease. Metabonomics is the study of metabolism in biologic systems in response to pathophysiologic stimuli and genetic modifications. In patients with varicose veins, there are significant differences in three important metabolic products; creatine, lactate, and myoinositol metabolites are increased and amounts of lipid metabolites are lower compared with nonvaricose control veins.⁸⁹ Analysis of the cellular metabolism in varicose veins, with signature end products, reflects the metabolism of the tissue and provides key information to the disease processes. Further research in this exciting field is necessary to have a better understanding of the processes leading to CVD and to determine whether patients with venous ulcers have certain characteristic metabolic profiles that will allow improved targeted therapy in both the prevention and active treatment of CVD and VLUs. Another potential mechanism for the development of CVD and VLUs is hypoxia in the dermis and apoptosis of the vein wall; however, studies evaluating these pathophysiologic alterations are more likely to be simple associations, with significant variability in results and therefore inconclusive.^{90,91}

CLINICAL EVALUATION

Guideline 3.1: Clinical Evaluation

We recommend that for all patients with suspected leg ulcers fitting the definition of venous leg ulcer, clinical evaluation for evidence of chronic venous disease be performed. [BEST PRACTICE]

For a leg ulcer to be classified as a VLU, there needs to be clinical manifestations consistent with CVD. Clinical evaluation should differentiate primary, secondary, or congenital venous problems and establish presence or absence of venous reflux, obstruction, or both. A thorough medical history should be performed to identify symptoms potentially related to venous disease, including extremity pain, burning aching, throbbing, cramps, heaviness, itching, tiredness, fatigue, and restless legs. Venous symptoms are usually exacerbated by limb dependency and relieved by rest or elevation. Medical history should also include risk factor assessment for venous disease, including age, body mass index, prior venous thromboembolism, family history of venous thromboembolism, family history of varicose veins, episodes of superficial thrombophlebitis, spontaneous venous rupture, prior use of compression therapy, prior venous operative interventions, use of venotonic medications, presence of other systemic diseases associated with leg wounds, and other possible associated medical factors that may contribute to nonhealing leg wounds. Physical examination for signs of venous disease should include inspection for telangiectasia, varicose veins, edema, chronic venous skin changes (skin discoloration, inflammation, eczema, hyperpigmentation, malleolar flair, corona phlebectatica, atrophie blanche, lipodermatosclerosis), healed ulcer, and active ulcer; palpation for varicosity, palpable venous cord, tenderness, induration, edema, and pulses; auscultation for bruit and reflux; and evaluation of ankle mobility.⁹²⁻⁹⁶

Guideline 3.2: Nonvenous Causes of Leg Ulcers

We recommend identification of medical conditions that affect ulcer healing and other nonvenous causes of ulcers. [BEST PRACTICE]

Differentiation of venous from nonvenous leg ulcers is important before initiation of therapy. In a defined Swedish population, prevalence of active leg ulcers was 0.31%, with 54% classified as venous and 46% nonvenous.⁹⁷ In a population-based study from Germany including 31,619 patients, venous reflux was the causative factor in 47.6%, arterial insufficiency in 14.5%, and combined arterial and venous reflux in 17.6%. Rarer causes included vasculitis (5.1%), exogenous factors (3.8%), pyoderma gangrenosum (3.0%), infection (1.4%), neoplasia

Table IV. Differential diagnosis for leg ulcers

Vascular disease
- Venous: post-thrombotic syndrome, varicose veins, chronic venous reflux
- Arterial: peripheral arterial occlusive disease, hypertension, arteriovenous fistulas, arterial thrombosis, embolism, dysplasia, thromboangiitis obliterans, aneurysm
- Lymphatic: lymphedema
- Microangiopathy: diabetes mellitus, livedoid vasculopathy
- Vasculitis
- Hypertensive arteriopathy
Neuropathic
- Peripheral neuropathy: diabetes mellitus, alcohol, medication, hereditary
- Central neuropathy: tabes dorsalis, myelodysplasia, syringomyelia, spina bifida, poliomyelitis, multiple sclerosis
Metabolic
- Diabetes mellitus, gout, prolidase deficiency, Gaucher disease, amyloidosis, calciphylaxis, porphyria, hyperhomocysteinemia
Hematologic
- Sickle cell anemia, thalassemia, polycythemia vera, leukemia, thrombocythemia, lymphoma, myeloplastic disorders, disorders of coagulation factors (factors I-XIII), coagulation inhibitors (antithrombin III, activated protein C resistance, protein C and S), or fibrinolysis factors (tissue plasminogen activator, plasminogen activator inhibitor, plasmin)
Autoimmune
- Rheumatoid arthritis, leukocytoclastic vasculitis, polyarteritis nodosa, Wegener granulomatosis, Churg-Strauss syndrome, systemic lupus erythematosus, Sjögren syndrome, scleroderma, Behçet disease, cryoglobulinemia
Exogenous
- Heat, cold, pressure, ionizing radiation, chemical, allergens, trauma
Neoplasia
- Basal cell carcinoma, squamous cell carcinoma (Marjolin ulcer), malignant melanoma, angiosarcoma, cutaneous lymphoma, papillomatosis cutis carcinoides, keratoacanthoma
Infection
- Bacterial: furuncles, ecthyma, mycobacterioses, syphilis, erysipelas, anthrax, diphtheria, chronic vegetative pyoderma, tropical ulcer
- Viral: herpes, variola virus, cytomegaly
- Fungal: sporotrichosis, histoplasmosis, blastomycosis, coccidioidomycosis
- Protozoal: leishmaniasis
Medication
- Hydroxyurea, leflunomide, methotrexate, halogens, coumarin, vaccinations, ergotamine, infiltration cytostatic agents
Genetic defect
- Klinefelter syndrome, Fely syndrome, TAP1 mutation, leukocyte adhesion deficiency, inherited hypercoagulable factors
Skin disorder
- Pyoderma gangrenosum, necrobiosis lipoidica, sarcoidosis, perforating dermatosis, Langerhans cell histiocytosis, papulosis maligna atrophicans, bullous skin diseases

Modified from Dissemmond J, Korber A, Grabbe S. Differential diagnosis of leg ulcers. *J Dtsch Dermatol Ges* 2006;4:627-34.

(1.1%), calciphylaxis (1.1%), and drug induced (1.1%).⁹⁸ Other medical conditions that can cause leg ulcers and affect ulcer healing should also be identified. Differential diagnosis of possible causes for leg ulcers is shown in Table IV.⁹⁹⁻¹⁰¹

Guideline 3.3: Wound Documentation

We recommend serial venous leg ulcer wound measurement and documentation. [BEST PRACTICE]

Serial VLU wound measurement and documentation are important to determine baseline markers and effect of subsequent treatment measures on healing parameters. Documentation should include number and position of ulcers on the leg. Wound measurements should be made for each VLU, including area, perimeter, and depth, with additional descriptors of wound edge parameters, wound base quality, drainage, and infection.

Adjuncts for standardization of ulcer documentation, including wound planimetry, digital photography, and digital planimetry software, are recommended.¹⁰²⁻¹¹³

Guideline 3.4: Wound Culture

We suggest against routine culture of venous leg ulcers and only to obtain wound culture specimens when clinical evidence of infection is present. [GRADE - 2; LEVEL OF EVIDENCE - C]

There is no evidence to support routine microbiology surface cultures of VLU in the absence of clinical signs of infection as these wounds are usually colonized by multiple micro-organisms. If there are no clinical signs of infection and the wound is responding to treatment, there is no indication to culture the wound.¹¹⁴⁻¹¹⁸

For patients with VLUs who develop associated clinical signs of infection, such as fever, leukocytosis, worsening

pain, cellulitis, purulence, increased exudate, malodor, discolored friable granulation tissue, biofilm, tissue necrosis, or ulcer progression, microbiologic cultures are recommended. Microbiology cultures can be obtained from wound surface or wound drainage by validated quantitative bacteriology swab methods with reproducible reliability compared with deep wound tissue biopsy and culture. Molecular techniques using polymerase chain reaction analysis may improve pathogen identification over standard swab culture methods.^{119,120} Deep wound tissue cultures should be reserved for wounds colonized with multiple micro-organisms when the bacterial pathogen is not clear from surface cultures, for biofilm infections, or for recurrent or persistent infection despite appropriate antimicrobial therapy.¹²¹⁻¹²⁵

Guideline 3.5: Wound Biopsy

We recommend wound biopsy for leg ulcers that do not improve with standard wound and compression therapy after 4 to 6 weeks of treatment and for all ulcers with atypical features. [GRADE - 1; LEVEL OF EVIDENCE - C]

When VLUs do not respond to standard wound and compression therapy, contributing factors should be considered, including infection and possible misdiagnosis. Whereas evidence does not support an absolute time frame, most evidence and clinical practice guidelines suggest tissue biopsy considerations within 4 to 6 weeks of nonresponsiveness to standard treatment. The biopsy specimen should be obtained from several sites, including the wound edge and central provisional matrix. Another consideration for tissue biopsy independent of time frame is differentiation of other possible nonvenous causes for leg ulcer. Although malignancy is rare, for any VLU with atypical features, wound tissue biopsy should also be performed.¹²⁶⁻¹²⁸ Although wound tissue biopsy provides valuable histologic differentiation, additional tissue analysis to include inflammatory cytokines and MMPs is still under investigation and does not have current clinical applicability.^{83,129,130}

Guideline 3.6: Laboratory Evaluation

We suggest laboratory evaluation for thrombophilia for patients with a history of recurrent venous thrombosis and chronic recurrent venous leg ulcers. [GRADE - 2; LEVEL OF EVIDENCE - C]

Several studies have shown that patients with VLUs have an increased prevalence of thrombophilia.¹³¹⁻¹³³ This association is increased in patients with documented thrombotic events, family history of thrombotic events, early-onset VLU before the age of 50 years, and recurrent or recalcitrant VLUs.¹³⁴⁻¹³⁶ Evidence supports selective laboratory evaluation for thrombophilia in all patients with VLU and a history

of recurrent venous thrombosis and chronic recurrent VLUs. Laboratory evaluation for thrombophilia should include testing for inherited hypercoagulable factors (antithrombin deficiency, protein C and protein S deficiencies), factor V Leiden (resulting in activated protein C resistance), prothrombin G20210A, plasminogen activator inhibitor type 1 mutations, hyperhomocysteinemia, antiphospholipid antibodies (anticardiolipin and lupus anticoagulant), and cryoglobulins and cryoagglutinins.

Guideline 3.7: Arterial Testing

We recommend arterial pulse examination and measurement of ankle-brachial index on all patients with venous leg ulcer. [GRADE - 1; LEVEL OF EVIDENCE - B]

Because adequate arterial perfusion is needed for improved healing, it is important to identify the presence of underlying peripheral arterial disease (PAD).^{137,138} Approximately 15% to 25% of patients with VLUs will have a concomitant PAD component.^{97,98,139,140} Evaluation of possible risk factors for PAD includes male gender, age, smoking, hypertension, dyslipidemia, diabetes, obesity, coexisting cardiovascular disease, stroke, renal insufficiency, hyperhomocysteinemia, and family history of cardiovascular disease. Symptoms and signs of PAD include claudication, rest pain, and ischemic ulceration or necrosis. Key components of the physical examination include measurement of blood pressure in both arms, cardiac auscultation, leg examination (changes in color, skin temperature, muscle atrophy, decreased hair growth, hypertrophied nails), and complete pulse examination (palpation for aneurysms; auscultation for bruits in carotid, aorta, or femoral region; palpation of the radial, ulnar, brachial, carotid, femoral, popliteal, dorsalis pedis, and posterior tibial artery pulse). Lower extremity Doppler examination is standard for patients with suspected PAD. Measurement of ankle-brachial index (ABI) is performed in the supine position with a sphygmomanometer cuff placed just above the ankle and a continuous-wave Doppler probe used to measure the systolic pressure of the posterior tibial and dorsalis pedis arteries of each leg, which is then normalized to the higher brachial pressure of either to calculate the ABI for each leg. ABI is calculated by dividing the systolic ankle pressure by systolic arm pressure. The reproducibility of the ABI varies, but it is significant enough that reporting standards require a change of 0.15 in an isolated measurement for it to be considered clinically relevant or >0.10 if it is associated with a change in clinical status. The typical cutoff point for diagnosis of PAD is $ABI \leq 0.90$ at rest, with $ABI \leq 0.50$ usually corresponding to critical limb ischemia. In patients with diabetes, renal insufficiency, or other diseases that cause vascular calcification, tibial vessels at the ankle become noncompressible, leading to a false elevation of the ankle pressure and ABI. In these patients, additional noninvasive diagnostic testing, such as pulse volume recordings or toe pressure measurement, should be performed to evaluate for PAD. For $ABI \leq 0.90$, referral should be made to a

vascular specialist for further arterial evaluation including comprehensive lower extremity arterial Doppler study, arterial imaging, and possible revascularization consideration before VLU compression or operative therapy.¹⁴¹

Guideline 3.8: Microcirculation Assessment

We suggest against routine microcirculation assessment of venous leg ulcers but suggest selective consideration as an adjunctive assessment for monitoring of advanced wound therapy. [GRADE - 2; LEVEL OF EVIDENCE - C]

Whereas objective microcirculation assessment by transcutaneous oxygen, laser Doppler perfusion, and capillary microscopy has shown correlation with healing of other wounds, there is insufficient evidence showing benefit for VLUs. Microcirculation assessment may be useful as an adjunct for mixed arterial and VLUs, when there is concern for adequate microcirculation related to other medical conditions involving capillary perfusion, or for monitoring of advanced wound therapy.¹⁴²⁻¹⁴⁴

Guideline 3.9: Venous Duplex Ultrasound

We recommend comprehensive venous duplex ultrasound examination of the lower extremity in all patients with suspected venous leg ulcer. [GRADE - 1; LEVEL OF EVIDENCE - B]

For a leg ulcer to be classified as a VLU, there needs to be objective documented evidence of venous disease. Ultrasound assessment needs to include evaluation for both obstructive and reflux patterns of venous disease. Whereas continuous-wave Doppler ultrasonography can be used, comprehensive color flow venous duplex ultrasound including B-mode gray-scale imaging, pulsed Doppler sampling, and color flow analysis has improved diagnostic accuracy and reproducibility and is the preferred first-line diagnostic test for all patients with suspected VLU.¹⁴⁵⁻¹⁴⁸

Comprehensive venous duplex ultrasound evaluates for both venous obstruction/DVT and venous reflux and includes the following components: direct visualization of deep, superficial, and perforator venous anatomic segments; compressibility; phasic venous flow with and without augmentation maneuvers; and documentation of venous reflux with measurement of valve closure time.^{149,150} Venous obstruction is present when thrombosis is directly visualized, noncompressibility of vein segment is present, phasic venous flow is absent with and without augmentation maneuvers, and extensive collateral vessels are present around the segment. To identify valvular incompetence, a portion of the venous duplex ultrasound examination should be performed in the upright or standing position. Augmentation maneuvers include Valsalva maneuver for common femoral vein and saphenofemoral junction and use of manual or cuff compression/release placed distal to the point of examination for lower extremity veins below the femoral junction.^{151,152} Most studies suggest criteria for valvular incompetence when valve closure time exceeds

≥ 1 second for femoral and popliteal veins and ≥ 0.5 second for great saphenous vein, small saphenous vein, tibial veins, deep femoral vein, and perforating veins.¹⁵³ However, use of ≥ 0.5 second for all superficial and deep vein segments can significantly improve the reliability of reflux detection.¹⁵⁴ Perforator vein is defined as pathologic when directional flow is from deep to superficial, valve closure time is ≥ 0.5 second, vein diameter exceeds 3.5 mm, and location of perforator is beneath healed or active VLU.^{155,156}

Venous duplex ultrasound not only provides diagnostic utility but also will identify patterns of venous disease that may have therapeutic implications.^{157,158} Because VLUs are usually associated with multilevel disease affecting the superficial, deep, and perforating veins, better defining these variable patterns of venous disease is critically important before any treatment. Evidence supports that 74% to 93% of all patients with VLUs will have superficial vein involvement, but superficial venous reflux will be isolated in only 17% to 54% of the limbs, the remainder of which will have either isolated or combined associated deep vein incompetence or obstruction or perforator incompetence.¹⁵⁹⁻¹⁶¹ Additional anatomic patterns of axial reflux directed to the bed of the VLU are important to be defined.¹⁶²

Guideline 3.10: Venous Plethysmography

We suggest selective use of venous plethysmography in the evaluation of patients with suspected venous leg ulcer if venous duplex ultrasound does not provide definitive diagnostic information. [GRADE - 2; LEVEL OF EVIDENCE - B]

Venous plethysmography (strain-gauge, air, or photoplethysmography) provides additional venous limb physiologic parameters regarding global venous reflux, outflow obstruction, and calf muscle pump function and has shown good correlation with venous duplex ultrasound.¹⁶³⁻¹⁶⁸ Some studies have shown utility for monitoring of venous functional changes and assessment of physiologic outcome of surgical treatments.¹⁶⁹⁻¹⁷² However, current evidence does not support a primary role for venous plethysmography as a diagnostic test for venous disease above venous duplex ultrasound. Venous plethysmography should be reserved for equivocal findings of venous duplex ultrasound examination, for recalcitrant or recurrent VLU, or if additional venous physiologic testing is required for diagnostic or therapeutic reasons.

Guideline 3.11: Venous Imaging

We suggest selective computed tomography venography, magnetic resonance venography, contrast venography, and/or intravascular ultrasound in patients with suspected venous leg ulceration if additional advanced venous diagnosis is required for thrombotic or nonthrombotic iliac vein obstruction or for operative planning before open or endovenous interventions. [GRADE - 2; LEVEL OF EVIDENCE - C]

Venous outflow obstruction has been underappreciated as a cause of venous hypertension and associated venous disease because of lack of a noninvasive screening

study that reliably identifies the problem.^{157,173} Venous duplex ultrasound of the femoral vein may provide indirect evidence of outflow obstruction with monophasic waveforms, loss of respiratory variation in the femoral tracing, or poor augmentation of the signal with distal limb compression.¹⁷⁴ Although the diagnostic accuracy of duplex ultrasound may be improved by performing direct duplex ultrasound examination of ilioacaval veins, reliable and reproducible imaging may be limited by body habitus, intestinal gas, and operator variability.¹⁷⁵ Use of venous plethysmography for identification of venous obstruction has also been described, but venous plethysmography is not widely available, limiting its usefulness as a screening modality.¹⁷⁶

For improved diagnostic accuracy, patients with VLU and suspected thrombotic or nonthrombotic venous obstruction should undergo additional contrast imaging with computed tomography venography (CTV) or magnetic resonance venography (MRV).¹⁷⁷⁻¹⁷⁹ In one study, 37% of patients with prior healed or active VLUs had evidence of ilioacaval venous obstruction >50% and 23% >80% on CTV or MRV, with a higher propensity in women, with prior history of DVT, and with evidence of deep venous reflux on duplex ultrasound.¹⁸⁰

Whereas screening CTV and MRV may provide additional information about potential venous outflow obstruction, diagnosis should be confirmed by contrast venography and intravascular ultrasound. Imaging with intravascular ultrasound with cross-sectional views of the vein and adjacent structures has high diagnostic accuracy in determining presence of ilioacaval thrombus burden or ilioacaval compression due to May-Thurner syndrome or other adjacent structures, which may have bearing on additional therapeutic options.¹⁸¹⁻¹⁸³

Guideline 3.12: Venous Disease Classification

We recommend that all patients with venous leg ulcer be classified on the basis of venous disease classification assessment, including clinical CEAP, revised Venous Clinical Severity Score, and venous disease-specific quality of life assessment. [BEST PRACTICE]

Accurate classification of venous disease is critically important for standardization of venous disease severity and assessment of treatment effectiveness. Classification systems for reporting of venous disease severity have been in existence for many years, with recent emphasis on both patient- and physician-generated assessment tools that can be used to follow clinically defined end points and changes over time.

The Clinical class, Etiology, Anatomy, and Pathophysiology (CEAP) classification, introduced in 1994 and revised in 2004, forms the basis for CVD documentation, and should be used for all patients with VLUs.¹⁸⁴⁻¹⁸⁶ The basic CEAP classification (Table V) is a simplified version of the more comprehensive CEAP and is recommended for clinical practice, with the more comprehensive CEAP reserved for research purposes. Whereas the CEAP classification system

Table V. Basic CEAP classification system

Clinical classification	
C0	No visible or palpable signs of venous disease
C1	Telangiectases or reticular veins
C2	Varicose veins
C3	Edema
C4a	Pigmentation and/or eczema
C4b	Lipodermatosclerosis and/or atrophie blanche
C5	Healed venous ulcer
C6	Active venous ulcer
CS	Symptoms, including ache, pain, tightness, skin irritation, heaviness, muscle cramps, as well as other complaints attributable to venous dysfunction
CA	Asymptomatic
Etiologic classification	
Ec	Congenital
Ep	Primary
Es	Secondary (post-thrombotic)
En	No venous etiology identified
Anatomic classification	
As	Superficial veins
Ap	Perforator veins
Ad	Deep veins
An	No venous location identified
Pathophysiologic classification	
Pr	Reflux
Po	Obstruction
Pr,o	Reflux and obstruction
Pn	No venous pathophysiology identifiable

Modified from Eklöf B, Rutherford RB, Bergan JJ, Carpentier PH, Gloviczki P, Kistner RL, et al. Revision of the CEAP classification for chronic venous disorders: Consensus statement. *J Vasc Surg* 2004;40:1248-52.

is useful to classify stages of venous disease, its components have been recognized to be relatively static and insufficient for determining changes in venous disease severity. For example, a patient presenting with an active VLU will be clinical CEAP-6 but when the ulcer heals can improve at best only to clinical CEAP-5. Despite this shortcoming, there has been general acceptance and wide dissemination of CEAP for both clinical and research purposes, making CEAP an essential component of venous disease classification.

In an effort to improve standardized outcome assessment of venous disease with gradable elements that can change in response to treatment, the Venous Clinical Severity Score (VCSS) was introduced in 2000 and revised in 2010 (Table VI). The VCSS system includes 10 clinical descriptors (pain, varicose veins, venous edema, skin pigmentation, inflammation, induration, number of active ulcers, duration of active ulceration, size of ulcer, and compressive therapy use), scored from 0 to 3 (total possible score, 30), that may be used to assess changes in response to therapy. VCSS has been shown to have minimal intraobserver and interobserver variability, and validation with objective venous parameters has been shown in a few studies.¹⁸⁷⁻¹⁹² The more recent revised VCSS (rVCSS) should be determined on initial evaluation and then at serial intervals for assessment of clinical outcome after nonoperative and operative treatment of VLUs and has been shown to be a better tool for assessing response to treatment.^{192,193} VCSS ≥ 8 indicates a patient with severe disease at risk for progression and warrants additional diagnostics or treatment.¹⁹⁴

Table VI. Revised Venous Clinical Severity Scoring (VCSS) system

	<i>None: 0</i>	<i>Mild: 1</i>	<i>Moderate: 2</i>	<i>Severe: 3</i>
Pain or other discomfort (ie, aching, heaviness, fatigue, soreness, burning) Presumes venous origin		Occasional pain or other discomfort (ie, not restricting regular daily activities)	Daily pain or other discomfort (ie, interfering with but not preventing regular daily activities)	Daily pain or discomfort (ie, limits most regular daily activities)
Varicose veins "Varicose" veins must be ≥ 3 mm in diameter to qualify in the standing position		Few: scattered (ie, isolated branch varicosities or clusters) Also includes corona phlebectatica (ankle flare)	Confined to calf or thigh	Involves calf and thigh
Venous edema Presumes venous origin		Limited to foot and ankle area	Extends above ankle but below knee	Extends to knee and above
Skin pigmentation Presumes venous origin Does not include focal pigmentation over varicose veins or pigmentation due to other chronic diseases	None or focal	Limited to perimalleolar area	Diffuse over lower third of calf	Wider distribution above lower third of calf
Inflammation More than just recent pigmentation (ie, erythema, cellulitis, venous eczema, dermatitis)		Limited to perimalleolar area	Diffuse over lower third of calf	Wider distribution above lower third of calf
Induration Presumes venous origin of secondary skin and subcutaneous changes (ie, chronic edema with fibrosis, hypodermatitis). Includes white atrophy and lipodermatosclerosis		Limited to perimalleolar area	Diffuse over lower third of calf	Wider distribution above lower third of calf
Active ulcer number	0	1	2	≥ 3
Active ulcer duration (longest active)	N/A	<3 mo	>3 mo but <1 y	Not healed for >1 y
Active ulcer size (largest active)	N/A	Diameter <2 cm	Diameter 2-6 cm	Diameter >6 cm
Use of compression therapy	0 Not used	1 Intermittent use of stockings	2 Wears stockings most days	3 Full compliance: stockings

Modified from Vasquez MA, Rabe E, McLafferty RB, Shortell CK, Marston WA, Gillespie D, et al. Revision of the venous clinical severity score: Venous outcomes consensus statement: Special communication of the American Venous Forum Ad Hoc Outcomes Working Group. *J Vasc Surg* 2010;52:1387-96.

On the basis of the association of chronic PTS with VLUs, additional classification of PTS should be performed for all patients with prior DVT. Several PTS scoring systems have been used both to diagnose and to classify PTS severity, including those described by Villalta,¹⁹⁵ Ginsberg,¹⁹⁶ Brandjes,¹⁹⁷ and Widmer.¹⁹⁸ Of these PTS scoring systems, the Villalta score (Table VII) has the highest degree of validation and has been shown to have excellent interobserver reliability, association with ambulatory venous pressures, correlation with severity of PTS, and ability to assess change in condition over time.¹⁹⁹⁻²⁰⁵ Evidence supports use of Villalta scoring in all patients with VLU and prior documented DVT to determine diagnosis, severity,

and treatment outcomes of PTS, with consensus recommendation to combine Villalta with CEAP for more accurate diagnosis of PTS.²⁰⁶

Additional venous disease evaluation should include patient-oriented quality of life (QOL) assessment. Both generic (36-Item Short Form Health Survey [SF-36]) and venous disease-specific (Venous Insufficiency Epidemiologic and Economic Study of Quality of Life/Symptoms (VEINES-QOL/Sym) questionnaires, the Chronic Venous Insufficiency Questionnaire (CIVIQ), the Aberdeen Varicose Vein Questionnaire (AVVQ), and the Charling Cross Venous Ulceration Questionnaire (CXVUQ)) have been used and validated for patients with venous

Table VII. Villalta scoring for post-thrombotic syndrome

<i>Symptoms and clinical signs</i>	<i>None</i>	<i>Mild</i>	<i>Moderate</i>	<i>Severe</i>
Symptoms				
Pain	0	1	2	3
Cramps	0	1	2	3
Heaviness	0	1	2	3
Paresthesia	0	1	2	3
Pruritus	0	1	2	3
Clinical signs				
Pretibial edema	0	1	2	3
Skin induration	0	1	2	3
Hyperpigmentation	0	1	2	3
Redness	0	1	2	3
Venous ectasia	0	1	2	3
Pain on calf compression	0	1	2	3
Venous ulcer	Absent		Present	

Villalta score ≥ 5 or if venous ulcer present: Villalta score of 5-9 mild, 10-14 moderate, and ≥ 15 severe.

Modified from Villalta S, Bagatella P, Piccioli A, Lensing AW, Prins MH, Prandoni P. Assessment of validity and reproducibility of a clinical scale for the postthrombotic syndrome [abstract]. *Haemostasis* 1994;24:158a.

disease.²⁰⁷⁻²¹⁴ Evidence supports inclusion of venous disease—specific QOL more than generic QOL assessment to be complementary to the more objective provider-based venous assessment tools. For all patients with VLU, QOL assessment should be performed with a venous disease—specific instrument to evaluate patient-reported outcome and severity of CVD.

Guideline 3.13: Venous Procedural Outcome Assessment

We recommend venous procedural outcome assessment including reporting of anatomic success, venous hemodynamic success, procedure-related minor and major complications, and impact on venous leg ulcer healing. [BEST PRACTICE]

For all patients with VLUs who require venous endovascular or operative intervention, outcome assessment should be performed to determine success of the procedure over time. Several surrogate outcome markers have been described for venous procedures, including anatomic parameters, venous hemodynamic success, procedure-related complications, and impact on VLU healing.²¹⁵ Use of recommended reporting standards and participation in a venous-based registry can facilitate tracking of venous procedure outcomes.²¹⁶ Clinical outcome assessment associated with wound and procedural treatments allows further determination of comparative effectiveness for improved VLU healing as mandated by the Institute of Medicine of the National Academies (<http://www.iom.edu/>) and the U.S. Food and Drug Administration (FDA).²¹⁷ In addition, standardized venous outcome assessment will translate to improved quality care measures as regulated by quality care organizations, such as the

National Quality Forum (<http://www.qualityforum.org/>), the Surgical Care Improvement Project (<http://qualitynet.org/>), the Joint Commission (<http://www.jointcommission.org/>), and the Agency for Healthcare Research and Quality (<http://www.ahrq.gov>), and increased potential opportunities for National Institutes of Health funding for research on venous ulcer prevention and treatment.³

WOUND CARE

A broad array of products and treatment strategies are currently marketed for the purpose of managing chronic wounds related to venous hypertension. It is challenging to determine which of these therapies have meaningful evidence that shows improvement in patient-centered outcomes, such as pain reduction and wound healing. This section is organized into general categories related to wound healing as noted in Table VIII. All of these therapies must be used concurrently with compression therapy or venous intervention to control the underlying venous hypertension resulting in ulceration.

Wound Bed Preparation. Wound bed preparation is defined as the management of the wound to accelerate endogenous healing and to facilitate the effectiveness of other therapeutic measures. The aim of wound bed preparation is to convert the molecular and cellular environment of a chronic wound to that of an acute healing wound. Included within this framework are (1) débridement, (2) wound exudate control, and (3) management of surface bacteria. Once control of the underlying venous hypertension is achieved, a key barrier that inhibits wound healing is eliminated. Other barriers to healing include bacterial overgrowth or infection, chronic inflammation, and necrotic or nonviable tissue on the wound surface. Control of these factors must also be achieved to stimulate optimal wound healing. Management of wound exudate is covered in the wound dressings section, and bacterial management is considered in the section on infection control.

Guideline 4.1: Wound Cleansers

We suggest that venous leg ulcers be cleansed initially and at each dressing change with a neutral, nonirritating, nontoxic solution, performed with a minimum of chemical or mechanical trauma. [GRADE - 2; LEVEL OF EVIDENCE - C]

Although there is little evidence that the routine use of a wound cleanser results in improvement of VLU outcomes measures, most patients with VLUs present with significant wound exudate and other debris in and around the wound area that must be cleansed routinely before dressing application. Numerous cleansing solutions have been described in this role with reasonable success.^{218,219} It appears that the main selection factor is to avoid routine use of a cleanser that would result in toxicity to the viable tissue in the wound bed.²²⁰

Table VIII. General categories of wound therapy for venous leg ulcers

Wound bed preparation
Wound cleansers
Débridement
Surgical débridement
Anesthesia for débridement
Hydrosurgical débridement
Ultrasonic débridement
Enzymatic débridement
Biologic débridement
Nutritional assessment and management
Measurement of wound progress
Wound infection and bacterial control
Wound culture
Indications for culture
Method of wound culture
Management of limb cellulitis
Wound colonization and bacterial biofilms
Treatment of wound infection
Topical antibiotics
Systemic antibiotics
Primary wound dressings
Topical dressing selection
Antimicrobials in topical dressings
Periulcer skin management
Anti-inflammatory dressings
Adjunctive wound therapies
Indications for adjunctive therapies
Split-thickness skin grafting
Cellular therapy
Use of cellular therapy
Preparation for cellular therapy
Frequency of cellular therapy application
Negative pressure therapy
Electrical stimulation
Ultrasound therapy

Guideline 4.2: Débridement

We recommend that venous leg ulcers receive thorough débridement at their initial evaluation to remove obvious necrotic tissue, excessive bacterial burden, and cellular burden of dead and senescent cells. [GRADE - 1; LEVEL OF EVIDENCE - B] We suggest that additional maintenance débridement be performed to maintain the appearance and readiness of the wound bed for healing. [GRADE - 2; LEVEL OF EVIDENCE - B] We suggest that the health care provider choose from a number of débridement methods, including sharp, enzymatic, mechanical, biologic, and autolytic. More than one débridement method may be appropriate. [GRADE - 2; LEVEL OF EVIDENCE - B]

Although protocols for management of VLU usually recommend wound débridement to remove nonviable tissue and to reduce bacterial burden, there is a lack of robust evidence that routine wound débridement accelerates wound healing. Williams et al prospectively studied 28 patients who underwent débridement for the presence of slough and nonviable tissue in the VLU bed compared with 27 patients who also had little granulation tissue but no slough and did not receive débridement.²²¹ Patients treated with débridement had a significantly higher wound size reduction

4 weeks after débridement than those who did not. This difference was maintained 20 weeks after débridement. Cardinal et al reviewed the relationship of débridement to ulcer healing in two prospective RCTs of topical wound treatments on 366 VLUs and 310 diabetic foot ulcers.²²² VLUs treated at a clinic visit with débridement had a significantly higher median wound surface area reduction in the week after débridement than did those for which débridement was not performed. However, débridement frequency per patient did not statistically correlate to rates of wound closure.

Recommendations to débride nonviable or necrotic tissue from the wound bed are supported by established principles of management of all wounds.^{223,224} However, the frequency and method of débridement are not well studied and have not been well established as related to the incidence of wound closure.²²⁵

Guideline 4.3: Anesthesia for Surgical Débridement

We recommend that local anesthesia (topical or local injection) be administered to minimize discomfort associated with surgical venous leg ulcer débridement. In selected cases, regional block or general anesthesia may be required. [GRADE - 1; LEVEL OF EVIDENCE - B]

The efficacy of topical anesthesia for débridement of venous leg ulcers was recently reviewed by the Cochrane Database.²²⁶ They identified six trials evaluating eutectic mixture of local anesthetics (EMLA) lidocaine-prilocaine cream compared with control.^{227,228} Patients treated with EMLA had significantly lower pain scores than those treated without topical anesthetic, leading to their conclusion that EMLA is an effective option for this purpose. For more extensive débridement, local infiltrative anesthetic, regional block, or general anesthesia may be required for adequate periprocedural pain control.

Guideline 4.4: Surgical Débridement

We recommend that surgical débridement be performed for venous leg ulcers with slough, nonviable tissue, or eschar. Serial wound assessment is important in determining the need for repeated débridement. [GRADE - 1; LEVEL OF EVIDENCE - B]

Guideline 4.5 Hydrosurgical Débridement

We suggest hydrosurgical débridement as an alternative to standard surgical débridement of venous leg ulcers. [GRADE - 2; LEVEL OF EVIDENCE - B]

Guideline 4.6: Ultrasonic Débridement

We suggest against ultrasonic débridement over surgical débridement in the treatment of venous leg ulcers. [GRADE - 2; LEVEL OF EVIDENCE - C]

Guideline 4.7: Enzymatic Débridement

We suggest enzymatic débridement of venous leg ulcers when no clinician trained in surgical débridement is available to débride the wound. [GRADE - 2; LEVEL OF EVIDENCE - C] We do not suggest enzymatic débridement over surgical débridement. [GRADE - 2; LEVEL OF EVIDENCE - C]

Guideline 4.8: Biologic Débridement

We suggest that larval therapy for venous leg ulcers can be used as an alternative to surgical débridement. [GRADE - 2; LEVEL OF EVIDENCE - B]

No method of débridement has been proved to be superior to surgical methods. However, in some cases, patients may not have ready access to a clinician trained to perform surgical débridement, or this method may be less desirable because of comorbid patient conditions or pain considerations. Hydrosurgical débridement was found in some studies to shorten the procedural time of débridement but may be associated with significant additional cost.^{229,230} Hydrosurgical débridement also requires a trained clinician and may be associated with significant periprocedural pain. No measurable benefit of the use of ultrasound methods to débride wounds has been reliably demonstrated. Enzymatic débridement, which does not require a trained clinician for application, has been found in several studies to remove nonviable tissue from VLU wound beds, but there is no evidence that this method provides a benefit over surgical débridement.²³¹⁻²³³ In clinical trials, larval therapy along with compression has been shown to be an effective method of débridement. However, the use of larval therapy did not increase the rate of healing for necrotic tissue or slough in leg ulcers compared with ulcers treated with hydrogel and compression.^{234,235} Barriers to the use of larval therapy also include personal hygiene concerns and personal bias. Recent adaptations have included containing the larvae in a bio-bag, which makes adoption more feasible to those with these concerns.

Wound Infection and Bacterial Control. The management of bacterial involvement of chronic VLUs is controversial, with limited high-quality research and contradictory results in the studies available for review. More robust information is available for the treatment of other infected chronic wounds, in particular diabetic foot ulcers. This information may not translate to the treatment of infected VLUs.

For indications and methods of wound culture, refer to **Guideline 3.4**. Although there is general agreement among experts that wounds with obvious signs of clinical infection should be treated with systemic antibiotics, there is no consensus on the management of wounds colonized with bacteria or bacterial biofilms without signs of systemic infection. The definition of a critically colonized wound is not universally standardized and may vary by the virulence of the colonizing bacteria. The more recent description of bacterial biofilms and the multiple species that are typically cultured from these wounds add another layer of complexity. Finally, the changing nature of bacterial behavior over time may render studies performed as recently as 5 to 10 years ago irrelevant.

Developing technology, which has allowed more detailed descriptions of the bacteria found existing in the

wound bed, employs methodology such as polymerase chain reaction analysis. These techniques may allow more specific tailored therapy for individual wounds. These methods, however, have not yet been established to improve outcomes in the care of VLUs. In this setting, definitive guidelines are difficult to establish, and treatment must be individualized on the basis of local bacterial epidemiology and patient conditions.

Guideline 4.9: Management of Limb Cellulitis

We recommend that cellulitis (inflammation and infection of the skin and subcutaneous tissue) surrounding the venous leg ulcer be treated with systemic gram-positive antibiotics. [GRADE - 1; LEVEL OF EVIDENCE - B]

Limb cellulitis is characterized by inflammation and infection of the skin, subcutaneous tissue, and lymphatic fluid and is most commonly due to streptococci or staphylococci, but it will occasionally include other species. There are numerous studies in the medical literature evaluating various systemic antibiotic regimens for the treatment of lower extremity cellulitis,²³⁶⁻²³⁸ also supported by a Cochrane review,²³⁹ with recommendation for initial treatment with antibiotics directed at gram-positive bacteria, reserving broader coverage for unresponsiveness.

Guideline 4.10: Wound Colonization and Bacterial Biofilms

We suggest against systemic antimicrobial treatment of venous leg ulcer colonization or biofilm without clinical evidence of infection. [GRADE - 2; LEVEL OF EVIDENCE - C]

The data available concerning the treatment of bacterial colonization of VLUs are insufficient and contradictory. Sibbald et al found that high bacterial counts in VLUs were associated with delayed healing.²⁴⁰ Improved healing was associated with reduction in bacterial counts. Davies et al suggested that bacterial density was predictive of nonhealing of VLUs.¹²² However, Lantis and Gendics found that when they treated VLUs with high bacterial counts with topical antibiotics, bacterial counts decreased but there was no correlation with improvement in wound size.²⁴¹ Finally, Moore et al reported that the specific bacterial species present or the number of species of bacteria present did not relate to healing outcomes.¹¹⁸ They concluded that their data supported no specific treatment of wound bacteria regardless of the type or quantity. On the basis of these contradictory findings, we are unable to generate useful supporting clinical guidelines for treatment of wound colonization or biofilm without clinical evidence of infection.

Guideline 4.11: Treatment of Wound Infection:

We suggest that venous leg ulcers with $>1 \times 10^6$ CFU/g of tissue and clinical evidence of infection be treated with antimicrobial therapy. [GRADE - 2; LEVEL OF EVIDENCE - C] We suggest antimicrobial therapy for virulent or difficult to eradicate bacteria (such as beta-hemolytic streptococci, pseudomonas, and resistant staphylococcal species) at lower levels of colony-forming units per gram of tissue. [GRADE - 2; LEVEL OF EVIDENCE - C] We suggest a combination of mechanical disruption and antibiotic therapy as most likely to be successful in eradicating venous leg ulcer infection. [GRADE - 2; LEVEL OF EVIDENCE - C]

Guideline 4.12: Systemic Antibiotics

We recommend that venous leg ulcers with clinical evidence of infection be treated with systemic antibiotics guided by sensitivities performed on wound culture. [GRADE - 1; LEVEL OF EVIDENCE - C] Oral antibiotics are preferred initially, and the duration of antibiotic therapy should be limited to 2 weeks unless persistent evidence of wound infection is present. [GRADE - 1; LEVEL OF EVIDENCE - C]

Although there is a lack of clinical studies evaluating the specific treatment of infected VLUs, available evidence supports systemic antibiotic treatment of patients with clinical evidence of infection and ulcers containing $>1 \times 10^6$ CFU/g of bacteria on quantitative culture.²⁴² Aggressive mechanical débridement of infected VLUs whenever possible is also suggested, although there is a lack of high-quality evidence indicating that débridement improves results in the treatment of infected ulcers.

Guideline 4.13: Topical Antibiotics for Infected Wounds

We suggest against use of topical antimicrobial agents for the treatment of infected venous leg ulcers. [GRADE - 2; LEVEL OF EVIDENCE - C]

There is a lack of evidence suggesting that topical antibiotics have a positive effect on the treatment of infected VLUs or on the healing of noninfected VLUs. Manizgata et al reported that in a prospective study of two silver-releasing dressings, neither dressing had an impact on the level of bioburden identified in treated VLUs.²⁴³ Conversely, in another study, Lantis and Gendics found that a sustained-release silver sulfadiazine foam reduced the level of bacteria cultured from infected VLUs, but there was no correlation with an improvement in wound size.²⁴¹ A Cochrane review on the use of topical silver for infected VLUs concluded that there is insufficient evidence to recommend the use of silver-containing dressings or topical agents for treatment of infected or contaminated chronic wounds.²⁴⁴

Primary Wound Dressings**Guideline 4.14: Topical Dressing Selection**

We suggest applying a topical dressing that will manage venous leg ulcer exudate and maintain a moist, warm wound bed. [GRADE - 2; LEVEL OF EVIDENCE - C] We suggest selection of a primary wound dressing that will absorb wound exudate produced by the ulcer (alginates, foams) and protect the periulcer skin. [GRADE - 2; LEVEL OF EVIDENCE - B]

There is insufficient evidence suggesting that a specific primary dressing that contacts the wound can result in a higher rate of wound closure. Most VLUs produce large amounts of exudate. This fluid contains high concentrations of proteases and inflammatory cytokines that may damage surrounding healthy skin.²⁴⁵ Removal of wound drainage from the wound bed will reduce the inflammatory environment that prohibits wound healing. We recommend use of dressings that will manage wound exudate and maintain a moist wound bed. Primary dressings with high absorptive capabilities, including foams, alginates, and other specialty dressings, are often selected for the primary coverage layer for heavily exudative VLUs.²⁴⁶

Guideline 4.15: Topical Dressings Containing Antimicrobials

We recommend against the routine use of topical antimicrobial-containing dressings in the treatment of noninfected venous leg ulcers. [GRADE - 2; LEVEL OF EVIDENCE - A]

In the only prospective RCT of topical antibiotics, which examined the treatment of noninfected VLUs, Michaels et al randomized 213 patients with VLUs to silver-releasing dressings compared with non-silver-releasing dressings.²⁴⁷ No significant difference in ulcer healing or other quality of life measures was identified in the silver dressing group. Given the increased cost of silver-containing dressings, routine use of topical antimicrobial dressings for the treatment of VLUs is not supported.^{248,249}

Guideline 4.16: Periulcer Skin Management

We suggest application of skin lubricants underneath compression to reduce dermatitis that commonly affects periulcer skin. [GRADE - 2; LEVEL OF EVIDENCE - C] In severe cases of dermatitis associated with venous leg ulcers, we suggest topical steroids to reduce the development of secondary ulcerations and to reduce the symptoms of dermatitis. [GRADE - 2; LEVEL OF EVIDENCE - C]

Management of dermatitis and other abnormalities of the periulcer skin is an important adjunct to other therapies in the treatment of VLUs.²⁵⁰ Venous hypertension may cause significant dermatitis in the calf and ankle that may be ameliorated with a variety of skin lubricants and other

agents. Contact dermatitis related to the dressings and other products used to treat VLUs is also frequent. Recognizing this problem and treating it expeditiously will prevent secondary skin ulceration complicating the primary leg ulcer.^{251,252} Consultation from dermatology may be useful in long-standing or recurrent cases experiencing sensitivity to wound treatment products.

Guideline 4.17: Anti-inflammatory Therapies

We suggest against use of anti-inflammatory therapies for the treatment of venous leg ulcers. [GRADE - 2; LEVEL OF EVIDENCE - C]

Although a significant body of research has identified that VLUs are associated with significant upregulation of inflammatory cytokines and proteases,^{71,83,253} there is a lack of data identifying that any anti-inflammatory dressing other than compression is associated with accelerated healing of VLUs.²⁵⁴

Adjunctive Wound Therapies

Guideline 4.18: Indications for Adjuvant Therapies

We recommend adjuvant wound therapy options for venous leg ulcers that fail to demonstrate improvement after a minimum of 4 to 6 weeks of standard wound therapy. [GRADE - 1; LEVEL OF EVIDENCE - B]

Adjunctive therapies for the healing of VLUs should be considered after all standard of care measures have been implemented. Comprehensive care should include compression therapy, local wound débridement, control of bio-burden, wound moisture balance with appropriate dressings, and consideration of the use of pentoxifylline. After a minimum of 4 to 6 weeks of appropriate care, a decrease in wound dimensions should be noted. Standard of care for VLUs will lead to improvement in the majority of cases, and only in those cases without improvement should adjunctive modalities be used. The cost of these therapies can be high, and the evidence supporting their use is not sufficiently strong to justify their use as primary therapy without an attempt at lower cost, evidence-based methods. However, failure to demonstrate improvement after 4 weeks of treatment with a decrease in wound size of at least 30% to 40% should lead the clinician to consider adjunctive treatment options.¹⁰⁹ Re-evaluation of the patient and wound should be performed before the use of adjuvant therapies to ensure that compression has achieved edema control, bio-burden is well controlled, and exudate is not excessive.

Guideline 4.19: Split-thickness Skin Grafting

We suggest against split-thickness skin grafting as primary therapy in treatment of venous leg ulcers. [GRADE - 2; LEVEL OF EVIDENCE - B] We suggest split-thickness skin grafting with continued compression for selected large venous leg ulcers that have failed to show signs of healing with standard care for 4 to 6 weeks. [GRADE - 2; LEVEL OF EVIDENCE - B]

There is currently insufficient information to recommend use of autologous skin grafting as a primary therapy for VLUs. Studies have bias, small sample size, and indirect comparators. A Cochrane review on skin grafting for VLUs also failed to reach a definitive recommendation.²⁵⁵ A recent RCT found that use of low-molecular-weight heparin resulted in decreased recurrence compared with skin grafting without anticoagulation.^{256,257} After skin grafting, patients should continue to use therapeutic compression.

Individual situations and patient preferences might result in the use of skin grafting for VLUs. Some clinicians consider skin grafting after standard of care has failed, for large soft tissue defects, by the patient's or clinician's preference, and when there are specific reasons that require more expeditious closure. In a nonrandomized study of 111 patients, Jankunas demonstrated improved healing and durability with skin grafting compared with conservative therapy for large venous wounds that were present longer than 6 months, but only 65% of cases were judged to have good take of the split-thickness skin graft.²⁵⁸ Skin grafting should be considered as primary therapy only for large wounds (ie, >25 cm²) in which healing is unlikely without grafting or as secondary therapy after there is a failure to achieve healing with standard of care.

Guideline 4.20: Cellular Therapy

We suggest the use of cultured allogeneic bilayer skin replacements (with both epidermal and dermal layers) to increase the chances for healing in patients with difficult to heal venous leg ulcers in addition to compression therapy in patients who have failed to show signs of healing after standard therapy for 4 to 6 weeks. [GRADE - 2; LEVEL OF EVIDENCE - A]

Apligraf, an allogeneic bilayer cellular therapy, has been approved by the FDA for treatment of VLUs. The efficacy of Apligraf was studied in an RCT of 245 patients with VLUs treated with standard of care compared with standard of care plus the application of Apligraf.^{259,260} VLUs had been present for at least 6 weeks and had not responded well to the initial use of compression and the other aspects of standard care. Subsequent research has identified improved outcomes for recalcitrant VLUs (>1 year duration or large surface area).²⁶² No other living cellular therapies have demonstrated benefit for the treatment of VLUs in prospective RCTs.

Guideline 4.21: Preparation for Cellular Therapy

We suggest a therapeutic trial of appropriate compression and wound bed moisture control before application of cellular therapy. [GRADE - 2; LEVEL OF EVIDENCE - C] We recommend that adequate wound bed preparation, including complete removal of slough, debris, and any necrotic tissue, be completed before the application of a bilayered cellular graft. [GRADE - 1; LEVEL OF EVIDENCE - C] We recommend additional evaluation and management of increased bio-burden levels before the application of cellular therapy. [GRADE - 1; LEVEL OF EVIDENCE - C]

Guideline 4.22: Frequency of Cellular Therapy Application

We suggest reapplication of cellular therapy as long as the venous leg ulcer continues to respond on the basis of wound documentation. [GRADE - 2; LEVEL OF EVIDENCE - C]

The optimal frequency and timing of reapplication of biologic skin substitutes to VLUs remain controversial with little consensus in published studies. The initial pivotal trial for Apligraf allowed up to five applications of the product during the first 3 weeks of the study.²⁵⁹ Reapplication was performed if the investigator thought that there was less than 50% "take" of the skin equivalent on inspection of the wound. Subsequent to this clinical trial, it has been determined that living skin equivalents do not persist in the wound for more than a few weeks, so "no take" occurs as is seen with autologous grafts. Other studies have reported application at variable times, including weekly, every few weeks, or once only.²⁶¹ With no comparative dosing studies published to determine clinical or economic outcomes, the frequency of application remains at the discretion of the clinician. Current clinical practice has included application of grafts followed by a period of 1 to 3 weeks of observation to determine effectiveness before reapplication is considered.

Guideline 4.23: Tissue Matrices, Human Tissues, or Other Skin Substitutes

We suggest the use of a porcine small intestinal submucosa tissue construct in addition to compression therapy for the treatment of venous leg ulcers that have failed to show signs of healing after standard therapy for 4 to 6 weeks. [GRADE - 2; LEVEL OF EVIDENCE - B]

Numerous tissue constructs are available for use in chronic wounds that employ either human tissue (amniotic membrane, cryopreserved skin) or animal tissue (bladder, fetal bovine skin, others). Some are reported to contain active growth factors or other attributes that might be beneficial to healing of VLUs.²⁶² Of the multitude of such products currently marketed, only porcine small intestinal submucosa has prospective RCT data supporting its use to accelerate VLU closure.²⁶³

Guideline 4.24: Negative Pressure Therapy

We suggest against routine primary use of negative pressure wound therapy for venous leg ulcers. [GRADE - 2; LEVEL OF EVIDENCE - C]

There is currently not enough information to support the primary use of negative pressure wound therapy for VLUs. Evidence supports positive effects with the use of negative pressure therapy for wound healing in general. Tissue granulation, area and volume reduction, and reductions in bioburden have all been reported. There have been

few studies specifically studying negative pressure therapy for VLUs, with most studies reporting on mixed wound causes.²⁶⁴ There has been an increase in the use of negative pressure wound therapy for wound bed preparation to augment skin graft healing.²⁶⁵

Guideline 4.25: Electrical Stimulation

We suggest against electrical stimulation therapy for venous leg ulcers. [GRADE - 2; LEVEL OF EVIDENCE - C]

There is theoretical, preclinical, and limited clinical evidence to support the use of electrical stimulation for the treatment of VLUs.²⁶⁶ However, few studies of electrical stimulation focus solely on VLUs. Also, there is little consistency in the parameters of treatment, including variability in type of electrical current, settings, treatment times, and preferred waveforms, making comparisons impossible.^{267,268} For these reasons, electrical stimulation is not recommended for the treatment of VLUs until further evidence supports its use.

Guideline 4.26: Ultrasound Therapy

We suggest against routine ultrasound therapy for venous leg ulceration. [GRADE -2; LEVEL OF EVIDENCE - B]

Therapeutic ultrasound has been found to stimulate a number of cellular effects associated with the acceleration of wound healing. These cellular effects have been well studied in vitro and include improvement of microcirculation, reduction of edema, and increases in cytokine and other protein levels that are active in the healing cascade.²⁶⁹ Clinical trials studying the effects of ultrasound have reported positive results in the healing of a variety of chronic nonhealing wounds.²⁷⁰ Clinical trials of therapeutic ultrasound for the healing of VLUs lack standardized protocols, and relatively few studies focus on VLUs alone. In a pilot study of VLUs refractory to compression therapy, ultrasound treatment was associated with a decrease in wound size, inflammatory cytokines, bacterial counts, and pain.²⁷¹ In an RCT of 337 VLU patients, weekly treatment with high-frequency ultrasound did not result in an increase in healing rates or improved quality of life compared with standard VLU care.²⁷² Unfortunately, most therapeutic ultrasound protocols have recommended treatment sessions at higher frequency, such as three times weekly or once daily. This has led to criticism of this trial as suffering from inadequate ultrasound dosing to determine whether it provides any benefit to patients with VLUs. Additional studies employing a standardized protocol of therapeutic ultrasound in patients with VLUs are required for further recommendations on the use of this modality to be made.²⁷³ On the basis of current literature, there is insufficient evidence to recommend the routine use of therapeutic ultrasound for the treatment of VLUs as a primary therapy.

On the basis of the literature review, there are three adjuvant treatments with evidence suggestive of benefit for patients with VLUs that do not respond to an initial treatment course of standard therapy. Split-thickness skin grafting may provide benefit, particularly for large, recalcitrant VLUs. Cellular therapy with Apligraf was found to be beneficial in a multicenter randomized clinical trial, as was porcine small intestinal submucosa. There have been no comparative trials of these therapies published with sufficient evidence to recommend one therapy over the others for the treatment of recalcitrant VLUs.

COMPRESSION

Compression therapy is based on a mechanical concept of applying pressure to the limb. This simple action causes multiple biologic processes proved to be beneficial for management of conditions ranging from occupational swelling to venous ulcers. A variety of devices have been used for compression therapy. Different types of bandages, bandage systems, and ready-to-use garments can provide sustained compression, whereas several pneumatic devices apply intermittent compression.

For the treatment of VLU, compression systems, which exert hemodynamic improvement on the dysfunctional venous pumping function, are preferred. Such systems that do not give way to the expanding muscle during walking are either short-stretch textiles or multicomponent bandages containing elastic material in combination with an adhesive or cohesive covering layer. Such bandages need to be applied by trained staff. Self-applicable and adjustable short-stretch Velcro band devices may be an alternative. Elastic bandages or compression stockings are effective concerning edema reduction but are hemodynamically less effective in improving the venous pumping function.²⁷⁴

Bandage layers should be differentiated from components. The term *multilayer* describes one bandage that always covers the leg with more than one layer because of overlapping during application. Every multicomponent bandage is a multilayer bandage, whereas graduated compression stockings have a single compression layer. The four-layer bandage (4LB) is a multicomponent bandage consisting of four components: orthopedic wool, crepe bandage, elastic bandage, and elastic cohesive (outer) bandage. Applying several components and layers over each other not only increases the pressure but also changes the elastic property of the final bandage because of the friction between the surfaces of each bandage and a cohesive outer layer, producing a final multilayer bandage that is less elastic and more stiff. Short-stretch bandages (SSB) are also often used as multicomponent bandages in combination with different materials. Unfortunately, the different combinations of materials are often poorly described in trials.

Coexistence of multiple devices that are designed to perform essentially the same function demonstrates that although compression therapy is generally effective, the optimization of compression has been a challenging task

because of limitations in current evidence. Use of confusing terminology and not reporting the dose (pressure) of a compression device and physical properties of the compression product are just a few of many deficiencies in available evidence related to compression therapy.²⁷⁵ The use of pressure-measuring devices at the skin-bandage interface to ensure adequate pressure applied during the bandaging is not routine; however, in specific circumstances (such as study protocol and quality assurance), such instruments can be applied.^{276,277}

Guideline 5.1: Compression—Ulcer Healing

In a patient with a venous leg ulcer, we recommend compression therapy over no compression therapy to increase venous leg ulcer healing rate. [GRADE - I; LEVEL OF EVIDENCE - A]

A total of nine RCTs compare compression therapy to no compression therapy, and these trials provide objective information on initial ulcer size as well as the outcomes of time to complete healing or proportion of ulcers healed (FDA-recommended end points of wound therapy trials). The preponderance of evidence suggests that VLUs heal more quickly with compression therapy vs no compression as confirmed by our commissioned comparative systematic review and meta-analysis of compression modalities and venous ulcer healing.³⁰

One RCT of 36 patients directly compared compressive (Unna boot) with noncompressive bandages (polyurethane foam dressing). Wound healing rates were significantly improved by 0.07 cm²/day ($P = .004$), and more patients completely healed in the compression group (RR, 2.30; 95% CI, 1.29-4.10).^{278,279}

A recent Cochrane review identified three RCTs encompassing a total of 177 patients comparing compression dressings with primary dressing alone (never with compression).²⁷⁹ One study (44 patients) showed a difference with improved ulcer area and volume at 8 weeks.²⁸⁰ Two of the studies (49 and 84 patients) failed to show a difference in healing rates between treatments at 7 weeks and 6 months of follow-up, respectively.^{281,282}

Another RCT of 321 patients compared SSB or 4LB with moist wound dressings without compression. The healing rate at 24 weeks was superior in both compression groups (72% SSB and 67% 4LB) compared with the non-compression group (29%; $P < .0001$).²⁸³

Three of four additional RCTs that compared compression dressings with standard wound care found improvement in ulcer healing with compression therapy. One study (53 patients) compared SSB with usual care and found complete ulcer healing at 3 months to be 71% in the SSB group compared with 25% in the usual care group (P value not reported).²⁸⁴ The remaining studies compared 4LB dressing with primary care management. A trial of 36 patients found more complete healing at 3 months in the compression group compared with the usual care group (RR, 4.0; 95% CI, 1.35-11.82).²⁸⁵ Similar

results were found in a larger trial encompassing 200 participants, with 54% of patients healed in the 4LB group compared with 34% in the control group ($P < .001$).²⁸⁶ Another RCT of 233 patients failed to find a difference between two groups with regard to complete healing at 1 year but did find improved rate of healing (median time of 20 vs 43 weeks; $P = .03$) favoring the compression group.²⁸⁷

Guideline 5.2: Compression—Ulcer Recurrence

In a patient with a healed venous leg ulcer, we suggest compression therapy to decrease the risk of ulcer recurrence. [GRADE - 2; LEVEL OF EVIDENCE - B]

The potential for recurrence of VLUs is high as demonstrated by a 67% recurrence rate in one study, in which 35% of patients exhibited a remarkable four or more episodes of ulceration.¹⁴⁰ The reported recurrence rate for ulcers in one study in the setting of compression therapy alone is 28% and in combination with superficial venous surgery is 12%, highlighting the recent improvements in clinical practice.²⁸⁸

As more success is achieved with healing of primary VLUs, the number of patients at risk for recurrence rises.²⁸⁹ However, few RCTs have specifically evaluated the impact of compression therapy on the risk of ulcer recurrence. One trial randomized 153 patients with recently healed (2 weeks) VLU to compression or no compression therapy. Compression hosiery with a high pressure (34-46 mm Hg) was associated with significant reduction in ulcer recurrence at 6 months compared with no compression (21% vs 46%; RR, 0.46; 95% CI, 0.27-0.76; $P = .003$).^{289,290} A second RCT of 188 patients randomized 166 into two treatment groups, each receiving therapy with 23 mm Hg compression at the ankle with two brands of stockings. Compliance data reported from this trial as summarized in Nelson and Bell-Syer demonstrated that inability to tolerate compression therapy was significantly associated with recurrent ulceration (RR, 2.58; 95% CI, 1.33-5.01; $P = .010$), although these patients were not included in randomization.^{289,291}

These RCT data are congruent with 15 years of observational data demonstrating that lack of compliance with compression therapy was significantly associated with ulcer recurrence (16% recurrence with compliance, 100% without; $P < .0001$).²⁹² Two studies to date have evaluated the use of moderate (UK class II, 18-24 mm Hg at the ankle) to high (UK class III, 25-35 mm Hg) compression and compliance with these stockings on prevention of ulcer recurrence, with differing results. One study found no difference in recurrence between the two groups but significantly lower compliance in the high-compression group.²⁹³ Because time to recurrence was not reported, the effect of compression pressures on delay of recurrence remains unknown.

On the basis of our commissioned comparative systematic review and meta-analysis of compression modalities and venous ulcer healing, low-quality evidence supports the effect of compression on ulcer recurrence.³⁰

Guideline 5.3: Multicomponent Compression Bandage

We suggest the use of multicomponent compression bandage over single-component bandages for the treatment of venous leg ulcers. [GRADE - 2; LEVEL OF EVIDENCE - B]

The possible difference in healing outcomes between single-layer and multilayer compression bandages has been evaluated in four trials, three of which have been published. In two trials, the number of participants was small ($n = 27$ and 34) and showed no difference between treatment groups.^{279,294,295} However, a large RCT with 245 patients demonstrated improved healing at 24 weeks (67% vs 49%; $P = .009$) in the multilayer (4LB) bandage group compared with the single-layer group.²⁹⁶ In addition, 4LB were associated with faster wound closure (78 vs 168 days; $P = .001$) compared with the single-layer group.

A recent meta-analysis identified six trials directly comparing multicomponent bandages containing elastic with those not containing elastic. Data from 797 patients (five trials with independent patient data available) demonstrated 30% improved healing with 4LB compared with those with SSB (odds ratio, 1.31; 95% CI, 1.09-1.58; $P = .0005$).²⁹⁷ These data might in part be explained by the skill of the health care professional in achieving optimal sub-bandage pressures and graduated compression. In comparing 4LB with SSB in countries where the medical staff is familiar with applying SSB (eg, Netherlands and Austria), there was no significant difference between the ulcer healing rates after 3 months (33 of 53 = 62% healed with 4LB vs 43 of 59 = 73% with SSB).²⁹⁷⁻²⁹⁹ Studies comparing different versions of the 4LB (proprietary and nonproprietary) were similar in outcomes, and thus a specific 4LB is not endorsed.³⁰⁰⁻³⁰²

On the basis of our commissioned comparative systematic review and meta-analysis of compression modalities and venous ulcer healing, moderate-quality evidence supports multicomponent compression over single component compression.³⁰

Guideline 5.4: Compression—Arterial Insufficiency

In a patient with a venous leg ulcer and underlying arterial disease, we do not suggest compression bandages or stockings if the ankle-brachial index is 0.5 or less or if absolute ankle pressure is less than 60 mm Hg. [GRADE - 2; LEVEL OF EVIDENCE - C]

An ABI of less than 0.5 is considered to be indicative of severe arterial disease.³⁰³ Compression of a limb with

significant arterial disease could compromise arterial perfusion and potentially result in adverse ischemic sequelae. In a survey study, nearly one third of general surgery consultants surveyed reported that they had encountered ulcers or necrosis as the direct result of compression treatment.³⁰⁴ Supporting evidence is limited to a small number of case reports and a dated physiology study that examined the effects of compression on the upper extremity in healthy subjects.³⁰⁵⁻³⁰⁷ However, one study using magnetic resonance flowmetry showed that sustained compression with a pressure around 40 mm Hg increases the arterial flow under the bandage in normal volunteers.³⁰⁸ Similarly, a recent study performed in patients with VLUs and concomitant arterial occlusive disease (ABI of 0.5 to 0.85) demonstrated by multiple metrics that arterial blood flow is even augmented by inelastic bandages.³⁰⁹

For patients with VLU and concomitant PAD, use of standard compression has been shown to be safe if ABI ≥ 0.80 .^{303,310,311} Modified compression bandages or compression stockings with lower pressure ratings can be used for ankle systolic pressure ≥ 60 mm Hg, digital pressure ≥ 30 mm Hg or ABI ≥ 0.50 with close monitoring, but only after consultation with a vascular specialist.^{309,312} Use of ankle perfusion pressure of 60 mm Hg or greater rather than ABI ≤ 0.5 as a cutoff for compression is preferred because this correlates better with tissue perfusion pressure, and any sustained external compression pressure should never exceed this cutoff perfusion pressure. One study showed that modified compression multilayered bandages with reduced compression pressure can be beneficial for healing of mixed ulcers.³¹¹

Guideline 5.5: Intermittent Pneumatic Compression

We suggest use of intermittent pneumatic compression when other compression options are not available, cannot be used, or have failed to aid in venous leg ulcer healing after prolonged compression therapy. [GRADE - 2; LEVEL OF EVIDENCE - C]

Intermittent pneumatic compression (IPC) was initially proposed as a method to promote VLU healing by activation of the fibrinolytic system and showed promise in decreasing VLU healing time in patients who had previously failed to respond to conservative treatment.^{313,314} However, this theory remains to be rigorously tested. To date, only 387 patients have been enrolled in RCTs comparing IPC with other treatment modalities.³⁶ Whereas it is advantageous to use IPC compared with no compression therapy, currently there is limited evidence to suggest that the addition of IPC to compression therapy offers benefit.³¹⁵ Thus, the patients likely to benefit most from IPC are those who cannot tolerate or do not have access to compression

therapy or who have failed to respond to prolonged compression therapy alone. Further studies need to be undertaken to evaluate the benefit of IPC in this particular cohort. In circumstances in which IPC is used, there is some evidence to suggest that proportion of ulcers healed (86% vs 61% at 6 months; $P = .003$) is improved with rapid compared with slow cycling.³¹⁶

OPERATIVE/ENDOVASCULAR MANAGEMENT

Guidelines for operative and endovascular management are categorized anatomically as superficial venous disease, perforator venous disease, deep infrainguinal venous disease, and ilio caval disease. Each category can be managed with open surgical or endovascular techniques. The rare occurrence of congenital venous disease leading to VLU and its treatment lacks definitive reporting.

These guidelines for operative and endovascular management also address the twofold goal of VLU treatment, which includes ulcer healing and prevention of ulcer recurrence. The separate pathologic processes of primary degenerative reflux disease and inflammatory thrombotic disease provide different challenges for the treating physician because the surgeon or interventionalist must provide a specific procedure to correct the pathologic state.

In general, quality of the evidence available to support recommendations for operative and endovascular management is mostly limited to level C evidence because of an absence of comparative prospective RCTs of treatment techniques, with the exception of superficial venous treatments. The strength of the clinical recommendations for operative and endovascular management can be increased by concurrence of results from individual case series and expert opinion of the Venous Ulcer Guidelines Committee.

This section is predicated on the principle that deep vein reconstruction is reserved for cases in which there has been failure to control the ulcer diathesis by dedicated nonsurgical measures and by simpler conventional interventions in the superficial and perforator veins of the extremity. In general, less invasive procedures are preferred when they are available and equally effective. Concurrence has been negatively affected because of the evolving developmental status of open surgery for complicated pathologic states in the deep veins of the leg, pelvis, and abdomen and the ongoing search for minimally invasive procedures. Within these limitations, there is growing consensus that the endovascular stenting techniques are the most appropriate surgical treatment for iliac occlusive disease, whereas open autogenous repair is best therapy for deep vein reflux in the infrainguinal lower extremity or from failed endovenous stent procedures of the ilio caval and iliofemoral venous system. A practical algorithm for operative and endovascular management of patients with VLUs is proposed in the Fig.

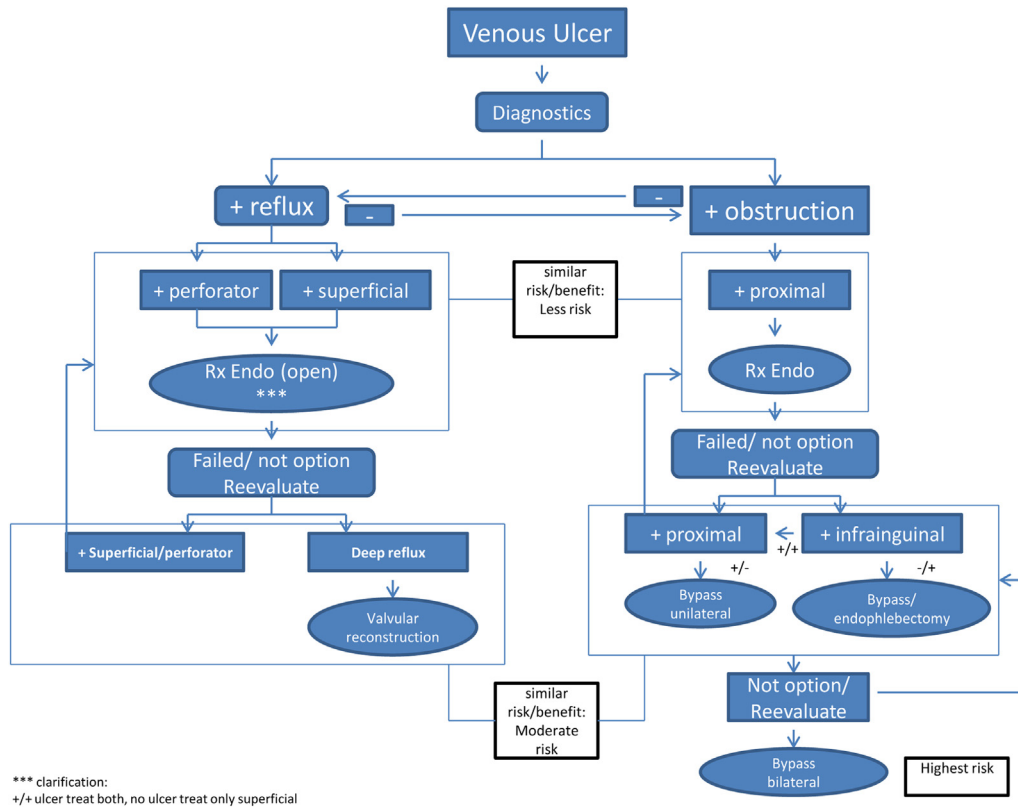


Fig. Proposed algorithm for operative and endovascular treatment of patients with venous leg ulcer (VLU) based on involved anatomic venous system and presence of venous reflux or obstruction. The risk-to-benefit ratio is weighed for those procedures with more risk (lower, moderate, higher) considered later in the treatment when the benefit is similar.

Superficial Venous Reflux and Venous Leg Ulcer

Guideline 6.1 Superficial Venous Reflux and Active Venous Leg Ulcer—Ulcer Healing

In a patient with a venous leg ulcer (C6) and incompetent superficial veins that have axial reflux directed to the bed of the ulcer, we suggest ablation of the incompetent veins in addition to standard compressive therapy to improve ulcer healing. [GRADE - 2; LEVEL OF EVIDENCE - C]

Guideline 6.2 Superficial Venous Reflux and Active Venous Leg Ulcer—Prevent Recurrence

In a patient with a venous leg ulcer (C6) and incompetent superficial veins that have axial reflux directed to the bed of the ulcer, we recommend ablation of the incompetent veins in addition to standard compressive therapy to prevent recurrence. [GRADE - 1; LEVEL OF EVIDENCE - B]

Our commissioned comparative systematic review and meta-analysis of surgical interventions vs conservative therapy including 11 studies (seven RCTs and four observational studies) favored open surgery vs compression for ulcer healing, although the quality of the evidence was low.³¹ In addition, other individual RCTs have shown a

difference that was not statistically significant favoring surgical treatment of the superficial venous system and compression over compression alone.^{31,288,317} On the basis of these observations, the strength and grade of evidence favoring surgery for ulcer healing are limited to a Grade 2C classification. Regarding recurrence, our commissioned comparative systematic review and meta-analysis included two RCTs, and each study favored surgery plus compression over compression alone to a statistically significant degree for prevention of ulcer recurrence.^{288,317,318} Because each study had some challenges in design and baseline imbalance, the strength and grade of evidence is 1B.

Regarding the choice of method of saphenous ablation, there are multiple RCTs showing strong and consistent evidence that modern open surgery, radiofrequency, and laser ablation are equivalent in effect and safety (Table IX).³¹⁹⁻³³⁰ Endovenous ablation can be extrapolated to be as effective as open ligation and stripping used in these earlier trials. Moreover, endovenous ablation can be carried out under local/tumescent anesthesia as an office-based procedure, which shifts the risk/benefit ratio significantly. Foam sclerotherapy has been demonstrated to rival these modalities and has significantly more recanalizations and refluxing treated segments on follow-up

Table IX. Randomized controlled trials of endovenous laser or radiofrequency ablation vs open surgery for the treatment of great saphenous vein incompetence (at least 1 year of follow-up) comparing recurrence of varicose veins and neovascularization

	Year	No. of patients	Follow-up, years	Results	
				Recurrence	Neovascularization
Endovenous laser ablation vs open surgery					
Lin et al ³¹⁹	2007	80	1	No difference	No difference
Theivacumar et al ³²⁰	2009	120	2	No difference	+ Laser
Christenson et al ³²¹	2010	200	2	No difference	No difference
Pronk et al ³²²	2010	130	1	No difference	No difference
Carradice et al ³²³	2011	280	1	+ Laser	No difference
Rass et al ³²⁴	2012	346	2	No difference	No difference
Rasmussen et al ³²⁵	2013	137	5	No difference	No difference
Endovenous radiofrequency ablation vs open surgery					
Lurie et al ³²⁶	2005	65	2	No difference	No difference
Perala et al ³²⁷	2005	28	3	No difference	No difference
Kianifard et al ³²⁸	2006	55	1	No difference	+ Radiofrequency
Stötter et al ³²⁹	2006	60	1	No difference	No difference
Helmy ElKaffas et al ³³⁰	2010	180	2	No difference	No difference

+ *Laser*, Favored in comparison of laser vs open surgery; + *Radiofrequency*, favored in comparison of radiofrequency vs open surgery.

evaluation.^{331,332} Several ablation techniques remain under investigation, including steam ablation and pharmacomechanical and cyanoacrylate ablation as well as CHIVA (ambulatory conservative hemodynamic management of varicose veins; one small RCT showed that CHIVA had a higher proportion of ulcers heal than with compression alone) and ASVAL (ambulatory selective varicose vein ablation under local anesthesia).^{20,257,333-338}

Guideline 6.3: Superficial Venous Reflux and Healed Venous Leg Ulcer

In a patient with a healed venous leg ulcer (C5) and incompetent superficial veins that have axial reflux directed to the bed of the ulcer, we recommend ablation of the incompetent veins in addition to standard compressive therapy to prevent recurrence. [GRADE - 1; LEVEL OF EVIDENCE - C]

Guideline 6.4: Superficial Venous Reflux With Skin Changes at Risk for Venous Leg Ulcer (C4b)

In a patient with skin changes at risk for venous leg ulcer (C4b) and incompetent superficial veins that have axial reflux directed to the bed of the affected skin, we suggest ablation of the incompetent superficial veins in addition to standard compressive therapy to prevent ulceration. [GRADE - 2; LEVEL OF EVIDENCE - C]

The evidence supporting this guideline is an extrapolation of the data on ulcer healing and prevention of ulcer recurrence stated under **Guidelines 6.1 and 6.2**. In this group of patients, VLUs had healed, and so intervention is expected to provide protection from recurrence as noted in our commissioned comparative systematic review and meta-analysis and the two RCTs.^{31,288,317,318}

Perforator Venous Reflux and Venous Leg Ulcer

Guideline 6.5: Combined Superficial and Perforator Venous Reflux With or Without Deep Venous Reflux and Active Venous Leg Ulcer

In a patient with a venous leg ulcer (C6) and incompetent superficial veins that have reflux to the ulcer bed in addition to pathologic perforating veins (outward flow of >500 ms duration, with a diameter of >3.5 mm) located beneath or associated with the ulcer bed, we suggest ablation of both the incompetent superficial veins and perforator veins in addition to standard compressive therapy to aid in ulcer healing and to prevent recurrence. [GRADE - 2; LEVEL OF EVIDENCE - C]

The evidence regarding treatment of perforator venous reflux associated with a VLU is complicated by several factors but most notably by combining its treatment with that of superficial venous reflux.³³⁹⁻³⁵² The Dutch RCT comparing subfascial endoscopic perforator vein surgery (SEPS) with or without superficial reflux ablation to medical treatment in patients with venous ulcers found no difference in healing rate or recurrence in the two treatment groups.³¹⁷ However, patients with recurrent ulceration or medially located ulcers in the surgical group had a longer ulcer-free period than did those treated in the conservative group ($P = .02$). A secondary analysis of the Dutch SEPS trial on 94 ulcerated legs was reported with a mean follow-up of 29 months.³⁵³ Ulcer recurrence was significantly higher in patients who had an incomplete SEPS procedure ($P = .007$), indicating the clinical significance of incompetent perforating veins in patients with venous ulcers.

A meta-analysis that included this RCT and 19 case series involving 1140 treated limbs found that surgical treatment by SEPS, with or without superficial venous ablation, resulted in ulcer healing in 88% and a low ulcer recurrence of 13% at 21 months.³⁴⁰ Another meta-analysis concluded that perforator interruption used as a part of a treatment regimen for severe CVI benefits most patients in the short term regarding ulcer healing and the prevention of ulcer.³⁴⁵

Guideline 6.6: Combined Superficial and Perforator Venous Reflux With or Without Deep Venous Disease and Skin Changes at Risk for Venous Leg Ulcer (C4b) or Healed Venous Ulcer (C5)

In a patient with skin changes at risk for venous leg ulcer (C4b) or healed venous ulcer (C5) and incompetent superficial veins that have reflux to the ulcer bed in addition to pathologic perforating veins (outward flow of >500 ms duration, with a diameter of >3.5 mm) located beneath or associated with the healed ulcer bed, we suggest ablation of the incompetent superficial veins to prevent the development or recurrence of a venous leg ulcer. [GRADE - 2; LEVEL OF EVIDENCE - C] Treatment of the incompetent perforating veins can be performed simultaneously with correction of axial reflux or can be staged with reevaluation of perforator veins for persistent incompetence after correction of axial reflux. [GRADE - 2; LEVEL OF EVIDENCE - C]

A recent systematic review that included analysis of 12 practice guidelines and four RCTs concluded that perforating vein interruption should be reserved for patients with large pathologic perforators with advanced CVI, and evidence suggests no added benefit in patients with less severe disease (C2, C3).³⁴⁰ The procedure can be performed either combined with or staged to follow superficial vein ablations, and those with long-standing and large medial ulcers or recurrent ulcerations have the chance to benefit most. In the North American SEPS registry, factors associated with ulcer healing included SEPS with concomitant ablation of superficial reflux and lack of deep venous obstruction ($P < .05$).^{354,355}

Guideline 6.7: Pathologic Perforator Venous Reflux in the Absence of Superficial Venous Disease, With or Without Deep Venous Reflux, and a Healed or Active Venous Ulcer

In a patient with isolated pathologic perforator veins (outward flow of >500 ms duration, with a diameter of >3.5 mm) located beneath or associated with the healed (C5) or active ulcer (C6) bed regardless of the status of the deep veins, we suggest ablation of the "pathologic" perforating veins in addition to standard compression therapy to aid in venous ulcer healing and to prevent recurrence. [GRADE - 2; LEVEL OF EVIDENCE - C]

There is no RCT that evaluated the effect of isolated perforator interruption on ulcer healing or recurrence.

Results of the SEPS registry, however, found that ulcer recurrence in 57 patients who underwent SEPS without saphenous ablation was not significantly higher than recurrence after combined venous surgery.³⁵⁴ Endovenous interventions, as discussed in **Guideline 6.8**, will undoubtedly bring new evidence to corroborate the efficacy of perforator ablations in the treatment of venous ulcers.

Guideline 6.8: Treatment Alternatives for Pathologic Perforator Veins

For those patients who would benefit from pathologic perforator vein ablation, we recommend treatment by percutaneous techniques that include ultrasound-guided sclerotherapy or endovenous thermal ablation (radiofrequency or laser) over open venous perforator surgery to eliminate the need for incisions in areas of compromised skin. [GRADE - 1; LEVEL OF EVIDENCE - C]

Endovenous techniques, including radiofrequency and laser ablations as well as foam sclerotherapy of perforating veins, have gained increasing acceptance because of the minimally invasive nature of these interventions.^{23,342-344,346-348,350} Therapy can be repeated with ease, risk of complications is minimal, and early to midterm results in case series are equivalent to or better than those reported after conventional perforating vein interruptions.³⁵⁶⁻³⁵⁸ The risks of open procedures, which specifically include infection, difficulty in healing of incisions required for treatment, increased local trauma, and need for general anesthesia, set open operations apart from these less invasive percutaneous methods. In one of the larger series of 140 consecutive endovenous ablation procedures (74 superficial and 66 perforator) on 110 venous ulcers in 88 limbs, there was measurable and significant reduction in ulcer size and ultimate healing after ablation of incompetent superficial and perforator veins in patients for whom conventional compression therapy had failed.^{337,348}

Deep Venous Obstruction/Reflux and Venous Leg Ulcer. For the following recommendations involving deep venous obstruction or reflux, patients with VLUs being evaluated for deep venous intervention should have already been evaluated and treated for any superficial or perforator reflux per **Guidelines 6.1 to 6.8**. For the remaining **Guidelines 6.9 to 6.17**, the status of the deep venous system is the only pathologic process requiring treatment. The risks of open procedures, which specifically include infection, difficulty in healing of incisions required for treatment, increased local trauma, hematoma formation, and need for general anesthesia, set open operations apart from the less invasive percutaneous methods. As a result, in patients with clinically significant iliac and caval obstruction combined with infrainguinal reflux or obstruction, percutaneous balloon angioplasty with stenting is suggested as the initial procedure over deep venous valvular reconstructions or open operative bypass procedures because it is much less invasive and presents less risk to the patient.

Guideline 6.9: Infrainguinal Deep Venous Obstruction and Skin Changes at Risk for Venous Leg Ulcer (C4b), Healed (C5) or Active (C6) Venous Leg Ulcer

In a patient with infrainguinal deep venous obstruction and skin changes at risk for venous leg ulcer (C4b), healed venous leg ulcer (C5), or active venous leg ulcer (C6), we suggest autogenous venous bypass or endophlebectomy in addition to standard compression therapy to aid in venous ulcer healing and to prevent recurrence. [GRADE - 2; LEVEL OF EVIDENCE - C]

Evidence is limited to case series and is further complicated by the variable combinations of reflux and obstruction that may be encountered from the calf to the inferior vena cava. There will frequently be a mixture of primary valve reflux and post-thrombotic secondary venous occlusion at different levels of the venous tree, and decisions as to the most critical site of disease have to be made from detailed preoperative anatomic analysis of the extremity veins. The principles that guide the choice of an individual procedure include the need for adequate inflow pressure and volume into and out of the repaired segments and preferential use of autogenous tissue for each element of the repair. Often, there is need to combine various techniques, such as endophlebectomy with bypass or with valve repair or venous transplantation. All of the techniques described in this and the following Guideline sections are potential choices that might be used in combination with endophlebectomy to provide the inflow and outflow needed for success. Evidence shows a preponderance of successful results for all techniques in 40% to 60% of cases with follow-up of 2 to 4 years.³⁵⁹⁻³⁷¹ Variations occur according to the status of the inflow vessels in the extremity and the outflow vessels from the common femoral vein.

On the basis of evidence for patients with lower extremity infrainguinal deep venous obstruction, autogenous venous bypass or endophlebectomy is suggested, depending on the status of inflow and outflow vessels.³⁶⁷⁻³⁷¹ Challenges exist with identification of physiologic degrees of obstruction and the quality of the obstructed vein that will determine the need for autogenous vein bypass conduit. Future expansion of endovascular techniques in combination with endophlebectomy can be predicted in this area.^{372,373}

Guideline 6.10: Deep Venous Reflux With Skin Changes at Risk for Venous Leg Ulcer (C4b), Healed (C5) or Active (C6) Venous Leg Ulcer—Ligation

In a patient with infrainguinal deep venous reflux and skin changes at risk for venous leg ulcer (C4b), healed venous leg ulcer (C5), or active venous leg ulcer (C6), we suggest against deep vein ligation of the femoral or popliteal veins as a routine treatment. [GRADE - 2; LEVEL OF EVIDENCE - C]

Ligation of the femoral and popliteal veins without well-demonstrated collateral pathways risks an increase of outflow

obstruction and is not recommended unless effective collaterals can be identified. Several case reports support ligation of the femoral vein as a method of eliminating physiologically significant reflux of the femoral vein when the collateral pathways of both great saphenous and deep femoral veins are patent and competent.³⁷⁴⁻³⁷⁷

Guideline 6.11: Deep Venous Reflux With Skin Changes at Risk for Venous Leg Ulcer (C4b), Healed (C5) or Active (C6) Venous Leg Ulcer—Primary Valve Repair

In a patient with infrainguinal deep venous reflux and skin changes at risk for venous leg ulcer (C4b), healed venous leg ulcer (C5), or active venous leg ulcer (C6), we suggest individual valve repair for those who have axial reflux with structurally preserved deep venous valves in addition to standard compression therapy to aid in venous ulcer healing and to prevent recurrence. [GRADE - 2; LEVEL OF EVIDENCE - C]

Several techniques are used to fashion an incompetent valve into a competent valve. External banding refers to a synthetic sleeve placed around the circumference of a valve to reduce the vein circumference and to produce a competent valve. External valvuloplasty is the technique of placing sutures along the valve attachment line of the intact vein to decrease the vein diameter with or without actually engaging the valve leaflets. The commissural angle is decreased with or without actual leaflet tightening to allow the valve cusps to properly appose and to prevent valve prolapse. Internal valvuloplasty requires open venotomy to allow direct visualization of the valve leaflets so that sutures can be accurately placed to reef or pull the cusps into alignment and to reduce redundancy until a competent valve has been restored.

External banding can achieve acceptable results in well-selected patients with early vein dilation. Long-term ulcer healing has been reported in about 50% of patients with one valve repair, and improved long-term results have been reported with multiple reconstructions.³⁷⁸⁻³⁸¹

External valvuloplasty results vary by technique, with the advocates of the “commissural repair” reporting a competency rate of ~60% and freedom from ulcer recurrence rate of ~70% at 3 years.³⁸² Others have reported lower competency (down to 32%) and ulcer-free rates (down to 50%) at 2 years. Proper patient selection is a critical variable in the results obtained. Overall, this technique appears applicable and effective in select patients, with expectations of a 50% ulcer-free rate at 2 years.^{377-380,383-390}

Internal valvuloplasty is an anatomically precise technique that has been modified over time. Although internal valvuloplasty provides the longest durability, it is technically more demanding and highly operator dependent. This technique is subject to higher complication rates than external repairs. Serial case series have demonstrated valve competency rates of 60% to 70% at 5 to 8 years and similar ulcer-free rates (Table X).^{368,377,391-396} Representative series of internal valvuloplasty interventions in patients with advanced disease show that most patients included in these studies had healed

Table X. Evidence summary for internal valvuloplasty

	Year	No. of limbs	Follow up, range (average), months	Valve Competent	Symptom resolved/healed
Ferris and Kistner ³⁹¹	1982	32	12-156 (72)	72.7%	81.2%
Ericksson ³⁹²	1990	19	44	68.4%	73.7%
Cheatle and Perrin ³⁹³	1994	52	3-54	85.2%	86.3%
Masuda et al ³⁷⁶	1994	32	48-252 (127)	77.5%	71.9%
Raju et al ³⁷⁸	1996	81	12-144	42.3%	76.5%
Sottiurai ³⁶⁸	1997	143	9-168	75%	75%
Perrin ³⁹⁵	2000	85	12-96 (58)	61.5%	71.4%
Tripathi and Ktenidis ³⁹⁶	2001	25	1-12 (6)	85.4%	84.0%
Tripathi et al ³⁷⁷	2004	90	(24)	79.9%	67.7%

or active VLUs. Essentially all studies demonstrate durable results in patient with VLUs that have proved recalcitrant to healing with other forms of treatment.^{363,391-393,397-399}

Among these are comparable studies performed independently by experienced venous reconstructive surgeons who report a consistent range of successful results with long-term follow-up at 1, 5, and 7 years.^{363,376,378}

Guideline 6.12: Deep Venous Reflux With Skin Changes at Risk for Venous Leg Ulcer (C4b), Healed (C5) or Active (C6) Venous Leg Ulcer—Valve Transposition or Transplantation

In a patient with infrainguinal deep venous reflux and skin changes at risk for venous leg ulcer (C4b), healed venous leg ulcer (C5), or active venous leg ulcer (C6), we suggest valve transposition or transplantation for those with absence of structurally preserved axial deep venous valves when competent outflow venous pathways are anatomically appropriate for surgical anastomosis in addition to standard compression therapy to aid in venous leg ulcer healing and to prevent recurrence. [GRADE - 2; LEVEL OF EVIDENCE - C]

Venous valve transposition requires that a competent valve, or one that can be made competent, be placed above the site where the incompetent venous systems are implanted into the axial vein. One example would be the presence of a competent valve in the proximal deep femoral vein, below which the incompetent femoral vein can be implanted to result in a then competent femoral venous system. In the select cohort of patients who are amenable to this intervention, a 40% to 50% competency rate with similar freedom from ulcer recurrence has been reported in a number of case series reports at 5 years of follow-up (Table XI).^{376,391,395,399-405}

Venous valve transplantation involves harvesting of a competent segment of vein that contains a competent valve from another extremity and implanting it into the femoral or popliteal position to provide a functioning valve in the affected extremity. Adjunctive use of endophlebectomy and the need for an arteriovenous fistula to increase flow through the reconstruction sites are additional considerations. The long-term competency rate at 2 to 5 years is ~50%, with a slightly higher freedom from ulcer recurrence rate.^{359-368,377,405,406} Table XII includes representative

Table XI. Evidence summary for venous valve transposition

	Year	No. of limbs	Follow-up, months	Valve competence	Ulcer recurrence
Johnson et al ⁴⁰⁰	1981	12	18	—	33%
Masuda et al ³⁷⁶	1992	14	120	40%	—
Sottiurai ⁴⁰¹	1996	20	9-149	40%	56%
Cardon et al ⁴⁰²	1999	16	24-120	75%	44%
Perrin ³⁹⁵	2000	17	12-168	53%	25%
Lehtola et al ⁴⁰³	2008	14	24-78	43%	—

series of venous valve transplantation conducted in patients with C3-6 disease, with most conducted in patients with C5,6 disease. Multiple small case series are reported with similar results for both techniques, with restored competence in the range of 40% to 60% for more than 2 years. Anatomic variations determine which procedure can be used in a given case. Both procedures can be effective for short-term ulcer healing, but both are subject to late failure of valve competence. A late failure of competence does not necessarily result in recurrence of ulceration.

Guideline 6.13: Deep Venous Reflux With Skin Changes at Risk for Venous Leg Ulcer (C4b), Healed (C5) or Active (C6) Venous Leg Ulcer—Autogenous Valve Substitute

In a patient with infrainguinal deep venous reflux and skin changes at risk for venous leg ulcer (C4b), healed venous leg ulcer (C5), or active venous leg ulcer (C6), we suggest consideration of autogenous valve substitutes by surgeons experienced in these techniques to facilitate ulcer healing and to prevent recurrence in those with no other option available in addition to standard compression therapy to aid in venous ulcer healing and to prevent recurrence. [GRADE - 2; LEVEL OF EVIDENCE - C]

Autogenous venous valve substitutes use venous tissue to make a functioning venous valve with pieces of vein tissue or endoluminal scar to fashion competent valves by various techniques. These include suturing of tissue in place within the opened vein; invagination of the stump of the great saphenous vein into the femoral vein with appropriate sutures placed to act as a valve; use of tacking sutures to secure the anterior

Table XII. Evidence summary for venous valve transplantation

	<i>Year</i>	<i>No. of limbs</i>	<i>Follow-up, range (average), months</i>	<i>Valve competent</i>	<i>Symptom resolved/healed</i>
Taheri et al ³⁶⁵	1986	46	8-36	91.7%	89.1%
Nash ³⁶⁶	1988	25	12-18	80%	92.0%
Iafrazi and O'Donnell ⁴⁰⁵	1997	15	(64)	92%	82%
Perrin ³⁶³	1997	30	12-120 (58)	30%	60%
Sottiurai ³⁶⁸	1997	33	8-169 (89)	38.7%	45.1%
Raju et al ⁴⁰⁶	1999	83	12-180	83%	60%
Tripathi et al ³⁷⁷	2004 ^a	38	(24)	47.5%	55.3%

^aImproved results with multiple valves repaired.

vein wall inside the vein lumen to act as valve, with a synthetic patch used to replace the anterior wall; and dissection of the intimal-medial wall of the often postphlebotic vein to form a monocuspid or bicuspid valve, with proper sutures placed to form a functioning valve. Regarding the first three techniques, small case series have been reported, but they lack corroborative series from other surgeons. Raju and Hardy reported five of seven patients to have healed recalcitrant VLUs within 4 months without recurrence during a 15- to 24-month observation period by use of the first technique.³⁸³ Great saphenous vein invagination has been reported in a single series, with 19 of 20 repairs remaining patent and competent at 10 months of follow-up, with all VLUs healing within 6 months and no recurrences observed.^{407,408} The valve made of the anterior vein wall with synthetic patch repair has reported excellent clinical results (80% or better) for the first year, but the number of cases reported is small.

Creation of monocuspid or bicuspid valves from the endoluminal lining of the post-thrombotic or even the primary diseased vein wall (neovalve) has been reported from a single site. It has undergone modifications over the years, and recent reports show 85% patency/competency rate with about 85% healed and ulcer-free recurrence rate at a mean of 28 months. All valves were patent. There was a 95% ulcer healing rate and two recurrent ulcers.^{409,410}

These techniques are performed in cases that are highly selected and have no other known valvular restorative potential. The procedures must be considered technically challenging and still in need of corroborative data before wider dissemination. Their use should be limited to experienced venous reconstructive surgeons in patients without other viable options.

Guideline 6.14: Proximal Chronic Total Venous Occlusion/Severe Stenosis With Skin Changes at Risk for Venous Leg Ulcer (C4b), Healed (C5) or Active (C6) Venous Leg Ulcer—Endovascular Repair

In a patient with inferior vena cava or iliac vein chronic total occlusion or severe stenosis, with or without lower extremity deep venous reflux disease, that is associated with skin changes at risk for venous leg ulcer (C4b), healed venous leg ulcer (C5), or active venous leg ulcer (C6), we recommend venous angioplasty and stent recanalization in addition to standard compression therapy to aid in venous ulcer healing and to prevent recurrence. [GRADE - 1; LEVEL OF EVIDENCE - C]

There is recognition of the importance of iliac vein obstruction in both primary and post-thrombotic CVD.^{175,411,412} Profound proximal obstruction in the ilio-caval veins appears to be the predominant hemodynamic pathophysiologic process compared with peripheral reflux when both exist, although definitive proof of this has not been tested. As a result, treatment priority is generally accorded to the proximal occlusive disease when one is faced with combined proximal obstruction and distal valvular reflux. Percutaneous iliac and caval vein stenting has been proved safe, with low morbidity, high patency, and satisfactory efficacy. Current results demonstrate a cumulative patency rate of 90% with ulcer healing rates of 60% to 80%, depending on the cohort being treated (Table XIII).^{173,413-418} Percutaneous iliac and caval vein stenting has become the preferred technique of many centers for ilio-caval and some common femoral vein occlusive/stenotic conditions, such as the post-thrombotic condition or that of the May-Thurner primary disorder when it is technically achievable.⁴¹⁹⁻⁴²⁷ Extension of the iliac vein stent below the inguinal ligament did not result in stent fracture, erosion, arteriovenous fistula, or higher incidence of stent thrombosis than is inherent to post-thrombotic disease.⁴²⁸ In the presence of combined iliac obstruction and infrainguinal reflux, treatment of the iliac obstruction is recommended as the first procedure, with repair of reflux below the iliac level reserved for persistently symptomatic cases.

Guideline 6.15: Proximal Chronic Venous Occlusion/Severe Stenosis (Bilateral) With Recalcitrant Venous Ulcer—Open Repair

In a patient with inferior vena cava or iliac vein chronic occlusion or severe stenosis, with or without lower extremity deep venous reflux disease, that is associated with a recalcitrant venous leg ulcer and failed endovascular treatment, we suggest open surgical bypass with use of an externally supported expanded polytetrafluoroethylene graft in addition to standard compression therapy to aid in venous leg ulcer healing and to prevent recurrence. [GRADE - 2; LEVEL OF EVIDENCE - C]

Most series suggest the need for large conduits from normal distal to normal proximal vein with supportive arteriovenous fistula to increase flow during early healing. No

Table XIII. Evidence summary for endovascular ilio caval stents placed for total venous occlusive disease

	Year	No. of limbs/limbs with ulcers	Follow-up, years	Cumulative patency	% Ulcers healed
Venous stenosis					
Hartung et al ⁴¹³	2009	89/6	7	93%	83%
Meng et al ⁴¹⁴	2011	272/78	5	94%	85%
Raju and Neglen ¹⁷³	2006	99/19 (inferior vena cava only)	4	82%	62%
Neglen et al ⁴¹⁵	2007	982/167	6	Nonthrombotic: 100%	58%
				Thrombotic: 86%	
Ye et al ⁴¹⁶	2012	224/63	4	99%	82%
Chronic total occlusions					
Raju and Neglen ⁴¹⁷	2009	139/32	4	66%	58%
Rosales et al ⁴¹⁸	2010	34/7	7	90%	57%

RCTs exist in this area, but credible series from specialized centers report a benefit and have been summarized in recent reviews.^{371,373,429-433}

Guideline 6.16: Unilateral Iliofemoral Venous Occlusion/Severe Stenosis With Recalcitrant Venous Ulcer—Open Repair

In a patient with unilateral iliofemoral venous occlusion/severe stenosis with recalcitrant venous leg ulcer for whom attempts at endovascular reconstruction have failed, we suggest open surgical bypass with use of saphenous vein as a cross-pubic bypass (Palma procedure) to aid in venous ulcer healing and to prevent recurrence. A synthetic graft is an alternative in the absence of autogenous tissue. [GRADE - 2; LEVEL OF EVIDENCE - C]

A number of case series report experiences with the cross-pubic bypass, a femoral vein to femoral vein bypass with use of autogenous vein. Patency has been based on clinical outcome and not objective assessment in earlier series, whereas more recent case series using venography or duplex ultrasonography to assess patency report 5-year secondary patency rates of ~75%. Risk factors for suboptimal outcomes include the low pressure in the venous system, a small saphenous vein (<5 mm), and technical imperfections such as kinking of the graft. A prosthetic bypass for venous obstruction is a salvage procedure when endovenous stenting or venous bypass is not feasible. Lower overall patency rates than with a Palma procedure can be expected.^{371,431,434-436}

Guideline 6.17: Proximal Chronic Total Venous Occlusion/Severe Stenosis (Bilateral or Unilateral) With Recalcitrant Venous Ulcer—Adjunctive Arteriovenous Fistula

For those patients who would benefit from an open venous bypass, we suggest the addition of an adjunctive arteriovenous fistula (4-6 mm in size) as an adjunct to improve inflow into autologous or prosthetic crossover bypasses when the inflow is judged to be poor to aid in venous leg ulcer healing and to prevent recurrence. [GRADE - 2; LEVEL OF EVIDENCE - C]

An adjunctive arteriovenous fistula has been used to enhance patency after venous procedures. An arteriovenous fistula can produce distal venous hypertension if the fistulas are too large. Because this pressure difference will negate the purpose of a venous bypass performed for relief of venous hypertension, use of an arteriovenous fistula should be temporary and its size should be controlled to avoid excessive flow. A suitably sized prosthetic sleeve around the fistula is one method to achieve this effect and allows later percutaneous closure with coil.⁴³⁷⁻⁴⁴⁰

ANCILLARY MEASURES

In addition to specific treatments for VLU, such as wound care, compression therapy, and operative/endovascular interventions described in prior guidelines, some ancillary complementary measures have been used to improve ulcer healing.⁴⁴¹⁻⁴⁴⁹ This section reviews nutrition, systemic drug therapy, physiotherapy, lymphatic massage, and balneotherapy options.

Guideline 7.1: Nutrition Assessment and Management

We recommend that nutrition assessment be performed in any patient with a venous leg ulcer who has evidence of malnutrition and that nutritional supplementation be provided if malnutrition is identified. [BEST PRACTICE]

Nutrition must be adequate to provide sufficient protein to support the growth of granulation tissue. Although most VLU patients are ambulatory and not as nutritionally depleted as patients who require frequent or chronic hospitalization, nutritional support is required if an individual is undernourished.^{450,451} Deficiency in vitamins A and E, carotene, proteins, and zinc was found in patients with VLUs.⁴⁵² In addition, elderly individuals susceptible to development of ulcers may have insufficient intake of proteins, vitamins, and minerals.⁴⁵³⁻⁴⁵⁵ These patients demonstrate improved ulcer healing rates when these deficiencies are corrected. However, no beneficial effect was demonstrated in supplementing patients without deficiencies.⁴⁵⁰

Whereas one small study⁴⁵⁶ reported healing of 13 of 18 patients with VLUs refractory to treatment after 4 months of oral administration of zinc sulfate (220 mg three times daily), five other trials failed to confirm these results.⁴⁵⁷

Guideline 7.2: Systemic Drug Therapy

For long-standing or large venous leg ulcer, we recommend treatment with either pentoxifylline or micronized purified flavonoid fraction used in combination with compression therapy. [GRADE - 1; LEVEL OF EVIDENCE - B]

Several systemic drugs have been evaluated for their potential role in improving VLU healing. Noting the limitation of oxygen diffusion in ulcerations by a pericapillary fibrin cuff,^{458,459} an RCT comparing stanozolol (anabolic steroid with profibrinolytic effect) with placebo was performed, but despite previously demonstrated activity on lipodermatosclerosis in CVD, the drug failed to show superiority over placebo.⁴⁶⁰ A randomized multicenter placebo-controlled trial of another profibrinolytic and antithrombotic drug, sulodexide (purified glycosaminoglycan), was encouraging and showed improved VLU healing in 235 patients treated for 3 months.⁴⁶¹ Platelet inhibitors have also been studied in RCTs of VLUs, but aspirin and ifetroban (oral thromboxane A₂ receptor antagonist) have failed to show beneficial effect on healing.^{462,463} Prostaglandin E₁ is known for properties that reduce white cell activation and platelet aggregation and increase vasodilation. An intravenous treatment with prostaglandin E₁ was tested in VLUs and demonstrated reduced time to healing, improved complete healing rate, and improvement in other outcomes pertinent to chronic venous disorders, such as edema and venous symptoms.⁴⁶⁴⁻⁴⁶⁶ The constraint of intravenous infusion (3 hours daily for 6 weeks), however, makes this therapy difficult to recommend. The discovery of the involvement of leukocytes in the pathophysiologic mechanism of VLUs has opened another pathway for successful investigations.⁴⁶⁷

Two systemic drugs interacting with leukocyte activation have demonstrated an effect on VLU healing, micronized purified flavonoid fraction (MPFF or Daflon)^{14,468-476} and pentoxifylline.^{286,474,477-483} MPFF protects the microcirculation from the damage induced by venous ambulatory hypertension. Clinical outcome measures in five RCTs of VLUs and a meta-analysis (723 patients involved) showed that adjunctive to compression therapy and local wound care, MPFF increased the healing rate (at 6 months, relative risk reduction was 32%; 95% CI, 3%-70%) and shortened time to ulcer healing,²⁹⁻³¹ with a favorable cost-effectiveness^{31,32} and improved venous symptoms.^{28,29} MPFF is used worldwide but is not FDA approved in the United States. Pentoxifylline was initially developed to treat PAD and has been used off label in VLUs. It has a powerful inhibitory effect on cytokine-mediated neutrophil activation, white cell adhesion to endothelium, and oxidative stress.⁴⁸⁴ In nine RCTs (eight vs placebo) including a total

of 572 patients, pentoxifylline combined with compression improved ulcer healing with a relative risk ratio compared with placebo of 1.4 [95% CI, 1.19-1.66].⁴⁷⁷

Guideline 7.3: Physiotherapy

We suggest supervised active exercise to improve muscle pump function and to reduce pain and edema in patients with venous leg ulcers. [GRADE - 2; LEVEL OF EVIDENCE - B]

The goal of physiotherapy in treating VLUs is to decrease venous pressure and edema. This can be achieved through activation of the calf muscle pump by specific exercises of the ankle or by biomechanical stimulation of the calf muscle pump. Lifestyle changes and a medical program of specific exercises (individual or in group) can improve both calf muscle function and ankle mobility. The improved function of the calf muscle pump results in both improved ejection fraction and residual volume of the venous reservoir. VLU patients showed significantly reduced values of ankle range of motion, walking speed and endurance, self-perceived exertion, mobility, and physical activity level.⁴⁸⁵⁻⁴⁸⁷ A recent literature review that studied the importance of lifestyle changes and self-care activities in preventing recurrence of VLUs identified 16 studies. This review concluded that there is some evidence to support a beneficial impact of increased physical activity, improved mobility, and foot exercises on lowering recurrence.⁴⁸⁸ A Dutch RCT investigated the effectiveness of the Lively Leg self-management program and showed a decrease in the duration of VLUs and increased use of leg exercises in patients who received the additional lifestyle counseling.⁴⁶¹ The time to recurrence and compliance to compression, however, were not affected. Other online coaching and home-based exercises programs were successfully developed.⁴⁸⁹⁻⁴⁹¹ Two prospective studies focused on the impact of supervised exercise. An RCT in patients with skin changes or ulceration demonstrated a significant improvement of calf pump function after a 6-month program of structured exercise.⁴⁹² Another study concluded that even a short 7-day period of supervised isotonic calf muscle exercises in patients with VLUs improves global hemodynamics in limbs with ulceration.⁴⁹³ A program of venous rehabilitation that includes four phases of training (warming, exercises on a specific bike, walking, and relaxation) showed some benefit in a recent study.⁴⁹⁴ Because mobilization of the foot and ankle joint increases venous refilling and reduces venous pressure, passive manipulation of the ankle has been also proposed, but there is no evidence of the beneficial effect for VLUs. Orthopedic treatment might be indicated for foot anomalies, but there is no evidence supporting improvement of venous plantar pump function.

Guideline 7.4: Manual Lymphatic Drainage

We suggest against adjunctive lymphatic drainage for healing of the chronic venous leg ulcers. [GRADE - 2; LEVEL OF EVIDENCE - C]

Massage of the leg to improve lymphatic drainage is well established as an effective therapy in patients with lymphedema. Manual lymphatic drainage increases the transport capacity of the lymphatics, stimulates development of lymphatic collaterals, and softens fibrotic tissue. This is suggested as a good adjunctive treatment in some resistant ulcers associated with venolymphatic edema, but there is no formal supporting evidence.⁴⁹⁵ One RCT showed that lymph drainage improved the mobility of the ankle joint affected by dermatofibrosis in patients with chronic ulcerated lesions but did not show benefit in ulcer healing.⁴⁹⁶

Guideline 7.5: Balneotherapy

We suggest balneotherapy to improve skin trophic changes and quality of life in patients with advanced venous disease. [GRADE - 2; LEVEL OF EVIDENCE - B]

Balneotherapy, spa therapy, or thermalism was studied in some European centers that specialize in the treatment of CVD.⁴⁹⁷ This complex therapy might benefit patients with VLUs because of mobilization of fluids and decrease of edema; improvement of venous hemodynamic, microcirculation, and skin oxygenation; and increase in circulatory treatment velocity. The efficacy of hydromassage therapy with thermal water has been demonstrated in patients with varicose veins. The beneficial results were attributed to the favorable action of hydrostatic pressure, which stimulated venous flow, as well as to the characteristics of the thermal water used in this study.⁴⁹⁸ Another trial also concluded that hydrotherapy may help patients suffering from primary varicose veins.⁴⁹⁹ An RCT showed that spa therapy, associated with balneotherapy and patient education, significantly and durably improved trophic skin changes, quality of life, and symptoms in patients with CVD but did not find a difference in VLU recurrences.⁴⁹⁷

Guideline 7.6: Ultraviolet light

We suggest against use of ultraviolet light for the treatment of venous leg ulcers. [GRADE - 2; LEVEL OF EVIDENCE - C]

Ultraviolet light has been proposed for the treatment of VLUs to increase skin blood flow and to reduce hypoxia. However, the results of one clinical prospective study showed that ultraviolet irradiation improves skin oxygenation for only 48 hours, and therefore it cannot be recommended until there is further supporting evidence.⁵⁰⁰

PRIMARY PREVENTION

VLUs develop because of ambulatory venous hypertension, which is related primarily to venous valvular reflux. Meaningful ways to prevent VLUs in patients at risk are effective but limited by lack of provider knowledge of diagnosis and treatment and patient compliance with the

primary means of prevention, which is compression. Equally important for prevention of VLUs in patients with DVT is adherence to evidence-based guidelines for prevention of DVT recurrence. In this section, current evidence for therapies related to primary prevention of VLUs is reviewed.

Guideline 8.1: Primary Prevention—Clinical CEAP C3-4 Primary Venous Disease

In patients with clinical CEAP C3-4 disease due to primary valvular reflux, we recommend compression, 20 to 30 mm Hg, knee or thigh high. [GRADE - 2; LEVEL OF EVIDENCE - C]

The concept behind compression is to reduce edema and inflammation related to venous hypertension in the lower limbs, particularly in the gaiter region, where VLUs are most likely to develop. Patients may progress from C2 to C3-C6 at 2% per year.⁵⁰¹ Patients with C₃₋₄ disease have a moderate risk of progressing to venous stasis ulceration, depending on their comorbidities and lifestyle habits.⁵⁰² One study has shown that approximately one third of patients with significant reflux progress in CEAP class during 19 months.⁵⁰³ Several risk factors for progression have been identified. Obese patients who stand for prolonged periods may be at higher risk than active nonobese patients, whereas patients with altered iron metabolism have been shown to have an increased risk for VLU.⁵⁵ Unfortunately, there are no prospective studies of large populations that define the risk of progression to C6 disease.⁵⁰⁴

Typically, limbs that go on to ulcerate have significantly worse ejection fraction and increased residual volume fraction by air plethysmography.⁵⁰⁵ Improvement in calf muscle function (ejection fraction) and reduced residual volume fraction are the primary mechanisms of compression.^{506,507} A recent meta-analysis showed that leg symptoms, primarily pain and edema, are also significantly improved with use of compression.⁵⁰⁸ The types of compression as well as the length and grade of the garment vary among the different manufacturers. Overall, no evidence exists that one type of compression, duration, or stocking length is more efficacious than any other. Negative gradient compression hose with up to 60 mm Hg calf and 50 mm Hg foot are associated with improvement in calf muscle pump function compared with graduated compression.^{509,510}

We recommend 20 to 30 mm Hg compression with the length (knee high or thigh high) determined by patient preference. Compliance with compression is important for its beneficial effect yet may not always be well documented or emphasized. Difficulty in application of compression garments may play a role in noncompliance, which may increase with higher compression levels.⁵⁰⁸ Other reasons exist for noncompliance, including transient conditions such as pregnancy or recent venous surgery.^{501,511} Good compliance produces effective results. For example, in a large population-based study, most patients with C1-4

disease found that compression therapy significantly improved swelling, heaviness, and pain with overall >70% compliance during 6-year follow-up.⁵⁰¹ Unlike treatment for VLU recurrence prevention, when compression is used for prophylaxis against VLU in those at risk, there is no evidence that high levels of compression are more effective than lesser. A meta-analysis of 11 RCTs of compression for CVI suggested that the level of compression needed to be at least 10 to 15 mm Hg, but higher levels were not necessarily beneficial.⁵⁰⁸ Thus, as a balance between effectiveness and compliance, the more moderate compression level is recommended. Last, follow-up after prescription of compression is important to address the patient's needs related to compression fitting and may be a way to enhance compliance. Although weak evidence exists, compression may decrease long-term costs associated with CVI. In a Markov decision analysis, use of compression was associated with an estimated savings of \$17,000 during a patient's lifetime.⁵¹² However, this study used a hypothetical patient with C5 disease and did not directly assess lower clinical classes of venous reflux. Regardless, this study provides support for use of compression in those at risk for VLU without significant downside to use of compression.

Guideline 8.2: Primary Prevention—Clinical CEAP C1-4 Post-thrombotic Venous Disease

In patients with clinical CEAP C1-4 disease related to prior deep venous thrombosis (DVT), we recommend compression, 30 to 40 mm Hg, knee or thigh high. [GRADE - 1; LEVEL OF EVIDENCE - B]

Venous reflux related to PTS typically is associated with more severe symptoms than is primary valvular reflux, progresses to a more severe CEAP class, and may confer increased risk for VLU.^{513,514} Venous occlusion does increase the risk of severe CVI, as the thrombus becomes a thick and collagen-dense occlusive lesion.⁵⁰³ Combined deep and superficial disease is likely after DVT and is associated with higher CEAP class.⁵¹⁵ The entire vein wall is often damaged by the thrombotic process, even with recanalization, as demonstrated by duplex ultrasound. Whether a segment of the deep vein system remains occluded or is recanalized, normal venous function is lost. After recanalization, the valves are incompetent, with significant reflux.⁵¹⁶

Given the more aggressive long-term course of PTS, we recommend 30 to 40 mm Hg compression hose, either knee or thigh high. Two large RCTs support the use of compression to decrease the occurrence of PTS.^{197,517,518} Overall, a reduction of ~50% was observed. Lesser compression strength, such as 20 to 30 mm Hg, is not as effective.⁵¹⁹ Multilayer compression is effective only for symptoms and not for development of PTS.⁵²⁰ The duration of compression for efficacy has not been rigorously determined by prospective studies.⁵²¹ However, per the current American College of Chest Physicians 2012 guidelines, use of compression stockings immediately after

diagnosis of DVT and continued compression for at least 6 months to 2 years are supported.⁵²² A large recent RCT calls this into question, but for now, we believe the harms for this therapy are low.⁵²³

Use of IPC may be helpful to relieve PTS symptoms, but its role in preventing VLU is unknown.^{524,525} Use of IPC should be based on individual assessments as little evidence exists. A small randomized crossover trial in patients with PTS found that compared with placebo-level pressure, IPC with a level of compression of 50 mm Hg was associated with a significant improvement in symptoms.⁵²⁴ However, the hard end point of VLU prevention was not assessed. Two other groups of patients who may benefit from IPC are those with severe difficulty in donning standard compression stockings and those who are immobile.^{526,527} Here, studies focusing on the physiology of decreased venous pressure and reduced interstitial edema suggest benefit for the latter group.

Guideline 8.3: Primary Prevention—Acute DVT Treatment

As post-thrombotic syndrome is a common preceding event for venous leg ulcers, we recommend current evidence-based therapies for acute DVT treatment. [GRADE - 1; LEVEL OF EVIDENCE - B] We suggest use of low-molecular-weight heparin over vitamin K antagonist therapy of 3-month duration to decrease post-thrombotic syndrome. [GRADE - 2; LEVEL OF EVIDENCE - B] We suggest catheter-directed thrombolysis in patients with low bleeding risk with iliofemoral DVT of duration <14 days. [GRADE - 2; LEVEL OF EVIDENCE - B]

The goal of DVT treatment is twofold: first, to prevent venous embolization to the pulmonary circulation from the thrombus; and second, to prevent propagation and recurrence of DVT, a direct factor for PTS. Venous stasis ulceration is the end-stage manifestation of PTS and is disabling and even limb-threatening.⁵²⁸ PTS treatment is primarily palliative, and thus prevention of DVT is paramount. There are numerous risk factors for PTS development,⁵²⁹ and recurrent DVT in the same segment of a prior DVT contributes most significantly to this process.⁵³⁰

Current well-established evidence-based guidelines are available from the 2012 American College of Chest Physicians guidelines.⁵²² Referral to this document for details and references, as the evidence-based recommendations are thorough, is recommended. There are several salient points for the treatment of acute DVT to summarize. First, rapid parenteral anticoagulation with either low-molecular-weight heparin or fondaparinux is indicated over intravenous unfractionated heparin (Grade 1A), as this may increase DVT recanalization.⁵³¹ Second, early use of compression is recommended, generally within 24 hours of diagnosis (Grade 2C). Third, early ambulation and limiting of bed rest are recommended.⁵³² Fourth,

transition from a parenteral agent to vitamin K antagonist with at least 3-month treatment is the minimum duration. In certain cases, consideration of the new oral anticoagulants, such as factor IIa or Xa oral inhibitors, may be indicated if the patient is intolerant of warfarin, although the evidence for these agents is less well documented.⁵³³ Last, a recent RCT suggests that low-dose aspirin may decrease recurrent DVT in those treated initially with 6 to 12 months of parenteral anticoagulation.⁵³⁴

Recent data, primarily from one study, suggest that low-molecular-weight heparin for 3 months may be more effective than a vitamin K antagonist for preventing PTS, with significantly fewer ulcers observed during 1 year of follow-up.⁵³⁵ A systemic review also suggested that low-molecular-weight heparin may decrease VLUs at 3 months by ~87%.⁵³⁶ More evidence is needed to confirm these results, and whether the new oral anticoagulants offer antifibrotic benefits remains unproven.

Long-term therapeutic anticoagulation is associated with lower DVT recurrence rates and, depending on the clinical circumstances of recurrence risk vs bleeding risk, should direct the duration of therapy.⁵²² An adjunctive measure to determine duration of anticoagulation is the measurement of D-dimer 1 month after cessation of anticoagulation. An RCT showed that if a patient's D-dimer level remains elevated, venous thromboembolism recurrence risk is significantly elevated (~2.5-fold), and continuation or reinstitution of anticoagulation is recommended, usually for life.⁵³⁷ If the D-dimer level is normal, cessation of anticoagulation is usually safe. Second, use of duplex ultrasonography for detection of residual vein wall thickening or obstruction (scar tissue, or "residual thrombus") may be beneficial, although the evidence is more variable in the literature, varying from 2.5- to 9.7-fold increased risk.^{538,539} If a patient has an extensively irregular or occluded long segment of vein, this may be a marker for increased risk of recurrent DVT, and thus continued anticoagulation may be beneficial.

Last, the use of catheter-directed thrombolysis compared with best medical therapy may significantly decrease PTS. The recent CaVenT trial compared best medical therapy with adjunctive catheter-directed thrombolysis in an RCT of patients with iliofemoral DVT.⁵⁴⁰ In 209 patients, the absolute risk reduction at 24 months was 14.4% (0.2%-28%) in PTS reduction, as assessed by Villalta score. However, several occurrences of major bleeding did occur, offsetting some of the benefit. In properly selected patients, the benefit of catheter-directed thrombolysis outweighs the risks, particularly with modern catheter thrombus removal techniques and experienced practitioners.⁵⁴¹

Guideline 8.4: Primary Prevention—Education Measures

In patients with C1-4 disease, we suggest patient and family education, regular exercise, leg elevation when at rest, careful skin care, weight control, and appropriately fitting foot wear. [BEST PRACTICE]

In patients with C3 and C4 disease of primary valvular reflux or C1-C4 disease related to DVT, we recommend regular ambulation or equivalent exercise, leg elevation when in bed or recumbent, good skin care to maintain skin moisture and to prevent drying and cracking, and footwear that is well fitted. Leg elevation is effective in patients with C4 disease by increasing microcirculatory flow.⁵⁴²

Although employing only a surrogate measure, a prospective study of exercise in 20 patients showed similar results in C5 patients, with an improvement in calf muscle pump function.⁵⁴³ A structured review also suggested a positive effect of exercise (ambulation) on calf muscle pump function, although not directly assessed for VLU occurrence.⁴⁴³ An RCT of structured exercise with 31 patients with C3 or higher clinical class venous disease showed improved calf muscle pump function compared with no specific exercise.⁴⁹² It is not uncommon for patients to have both venous reflux and diabetes, and standard guidelines in foot care for diabetics have been produced.⁵⁴⁴

Evidence for all these measures in preventing VLU is weak. In consideration of shoe types, one study suggested that high heels may decrease hydrostatic pressure at the ankles.⁵⁴⁵ A separate study using air plethysmography showed that high heels were associated with decreased ejection fraction and increased residual volume fraction.⁵⁴⁶ However, specific footwear and risk of VLU has not been tested, but caution should be exercised in those with C3 or higher clinical class venous disease. One study also suggested that correction of pedal podalic angle with special insoles may increase the calf muscle pump function.⁵⁴⁷

No data exist for educational interventions in those with CVI to prevent VLU. However, the cost of and risk to patients and family education are likely to be reasonable, with little potential for harm. Knowledge of family history of maternal venous reflux is important as a prognostic factor for development of VLU.⁵¹³ Moreover, education of caregivers who interact with patients with C1 to C4 disease is equally important. It is recommended that all vascular specialists make the effort to educate primary caregivers.

Guideline 8.5: Primary Prevention—Operative Therapy

In patients with asymptomatic C1-2 disease from either primary or secondary causes, we suggest against prophylactic interventional therapies to prevent venous leg ulcer. [GRADE - 2; LEVEL OF EVIDENCE - C]

In patients with C1-2 disease from either primary or secondary causes, it is unclear if interventional therapies prevent long-term VLU occurrence, in contrast to good supporting evidence for surgery and VLU recurrence. A direct link between early treatment of superficial venous reflux and long-term VLU incidence is only circumstantial. In a large study from Nelzen, a 50% reduction in VLU was found to correlate with a better diagnosis and treatment of superficial disease.²¹ Whereas there have been no trials assessing primary VLU prevention in those with C1-2

disease, superficial venous interventions for secondary prevention decrease recurrent VLU.²⁸⁸ Similarly, there is no evidence that prophylactic repair of the deep venous valvular system can decrease long-term VLUs in those patients who have not manifested any such entity.

The goal of surgical treatments should be to improve the patient's symptoms, including leg pain, swelling, and discomfort. To achieve this goal, numerous interventions exist for treatment of superficial venous disease as well as deep system disease for secondary prevention of VLU, specified in the section on operative/endovascular management and in other guidelines for comprehensive management of superficial venous disease.²³

FUTURE DIRECTIONS/CONCLUSIONS

The SVS/AVF Evidence-Based Clinical Practice Guidelines for Management of Venous Leg Ulcers is the end result of a programmatic initiative by the AVF "to reduce the incidence of venous ulcer 50% over the next decade"²⁹ combined with the need for clinical practice guidelines for VLUs, as recognized by the SVS Document Oversight Committee. With the primary target audience for these guidelines, specialists who treat VLUs, the current guidelines attempt to update as well as to address gaps in prior VLU guidelines. A recent systematic analysis of existing VLU guidelines demonstrated concordance in certain areas but significant management gaps in others, such as advanced wound therapies, role of thermal ablation of superficial venous disease, valve reconstruction, and treatment of outflow obstruction by stenting, all of which were not addressed in previous guideline documents.¹⁸ Toward that end, formal new systematic review and meta-analyses were performed for two areas, compression and surgical/endovascular treatments.^{30,31}

The current SVS/AVF clinical practice guidelines are based on the best level of evidence currently available for a recommendation. The strength of a recommendation for a specific guideline is tempered by the quality of evidence supporting that recommendation. The SVS/AVF Joint Clinical Practice Guidelines Committee has reviewed the grading of recommendations within each subcommittee and as an overall group with an eye toward a critical assessment. Overall, the evidence level for venous ulcer management is mostly of moderate strength, and as a consequence, most recommendations as a whole achieve lower grades, Grade 2B (18.6%) and Grade 2C (53.3%); in some instances, the recommendations may not be graded and are designated Best Practice (10.7%). Parenthetically it should be noted that the current American College of Chest Physicians guidelines for antithrombotic therapy and prevention of thrombosis contain no Grade 1A recommendations.⁵²² This observation points to the need for more well-done randomized controlled studies on the management of VLUs. Whereas the current VLU guidelines attempt to cover the state of evidence as it exists today, as more evidence comes to fruition, updates and modifications will be required on an ongoing basis, so that these VLU guidelines become "living documents."

The treatment of VLU currently is hampered by a siloed approach, that is, just focusing on ulcer healing or ulcer recurrence rather than on the continuum of care. For expressing and assessing cost/resource utilization as well as quality of outcomes, how long the skin remains in an ulcer-free state (ulcer-free interval), as expressed by the percentage of the follow-up period that the skin is ulcer free, is a more valuable metric.

Key points from the current guidelines and areas of evidence needed to assist with future directions for VLU management are summarized as follows.

Venous Ulcer Definition and Pathophysiology

A classification system of VLU into meaningful groups in which comparative studies with different treatments can be carried out is needed. This is necessary and cogent because there is such diversity of disease entities under the broad term *venous ulcer*. **Pure venous ulcer:** Reflux into ulcer region by any route superficial or perforator or deep without identifiable additional disease. **Mixed venous ulcer:** Reflux or obstruction creating venous hypertension in region of venous ulcer in presence of identifiable additional disease.

Additional pathologic processes that are risk factors for venous disease need to be categorized, such as arterial occlusive disease, infection, inflammatory (dermatitis, allergic, autoimmune), lymphedema, and morbid obesity. Each of these disease processes presents additional barriers that may require separate adjunctive treatment for the ulcer to heal. If untreated, they can prolong healing even after correction of venous reflux.

The study of the inflammatory cascade that allows benign reflux to cause tissue changes leading to and becoming VLU needs to be expanded. Understanding of why some patients who have varicosities down to the ankle associated with long-standing venous reflux can convert to CEAP C4b-C6 severity is missing. If the cause is inflammation, then specific treatment of the inflammatory problem with steroids or other measures may need to be included in addition to correction of the reflux or obstruction.

Clinical Evaluation

The current management of VLU depends on accurate identification and assessment of the presence of venous disease underlying wound behavior. Accurate anatomic and functional venous and wound classification is required. Whereas duplex ultrasound is an essential tool in achieving venous disease diagnosis, additional imaging modalities that aid in assessing wound biology and the physiologic impact of wound and venous disease therapy are needed. The role of outflow imaging for patients with suspected ilio caval stenosis/occlusion requires further development. Additional validation of venous disease and wound classification systems and quality outcome measures is needed to allow better comparative analysis evidence of therapeutic modalities.

Wound Care. The wound care field continues to evolve and expand. Drivers include an aging society, increasing prevalence of obesity and other comorbid

conditions, and an ever-expanding therapeutic arsenal of new treatment technologies. The current VLU guidelines address the most important clinical issues surrounding advanced wound care, including wound bed preparation, control of bacterial colonization and infection, and débridement techniques and frequency, which are all critical to achieving healing outcomes. Novel diagnostic methods under development for the rapid identification of bacteria and inflammatory cytokine levels will likely result in the need for additional comparative effectiveness research in the near future for clinicians to decide on best practice options. Use of these diagnostic modalities may allow patient-specific therapeutics to enhance the potential for rapid wound healing.

A broad range of therapeutic modalities employing various forms of electromagnetic energy transfer may be used adjunctively for the healing of chronic wounds. Currently, there is a lack of standardization concerning energy settings, treatment frequency, and methods of energy delivery, making firm recommendations difficult. There are more treatments under evaluation presently, with some methods combining energy sources. These data will need to be evaluated in future updates. Last, there has been recent expansion of cellular and acellular biologic dressings. These products can be human or animal derived and come in myriad formats. Currently, there are no comparative effectiveness studies available to help guide the clinician to make appropriate decisions on use of these products. Evidence in this expanding field will need to be evaluated so that populations of patients who would benefit the most from specific tissue products can be identified. A significant role for patient-centered outcomes measures also needs to be incorporated into trial design in the future. The patient's preferences will need to be balanced with clinical efficacy and economic factors in the face of health care reform.

Compression

The use of compression has been a fundamental treatment component for VLU, but certain knowledge gaps still exist. Objective measures of the "dose" of compression should be used in future studies. These measures, which include resting interface pressure at a standard point and stiffness (change in this pressure during standing and walking), need to be factored into compression effectiveness. These objective measures should replace such current classifications as "elastic" and "inelastic" bandages, especially for multibandage systems. The real behavior of a bandage and bandage system is not the elastic property tested in the laboratory but its clinical behavior on the leg. Even a single bandage applied with overlaps becomes a multilayer wrap with different mechanical properties. The friction between multiple layers increases stiffness of the wraps, especially when the surface of a component is adhesive or cohesive and when substances like zinc paste are used.

In assessing the role of compression, there are other needs. Standard training with objective quality control

should be used in studies of bandages and bandage systems; most of the comparative studies to date were performed in centers inexperienced with short-stretch material. A large-scale RCT is needed to study whether compression prevents the recurrence of venous ulcers. The role of IPC in treatment of venous ulcer patients needs to be defined, especially in patients who cannot tolerate compression therapy or who have failed to respond to prolonged compression therapy alone. Finally, methods for assessing the patient's compliance with wearing of these garments/devices that are better than "patient diaries" should be developed. These monitoring devices are being employed in the treatment of other diseases, like the diabetic foot.

Operative/Endovascular. Unfortunately, the quality of evidence to support recommendations for operative and endovascular management is limited to level C evidence. This lower level of evidence is due to the absence of comparative prospective RCTs, with the exception of a few studies that address treatment of superficial venous disease. Even the data in the treatment of superficial insufficiency, as suggested by the commissioned meta-analysis, are limited in scope. The data derived from open procedures (ligation and stripping RCTs) have been extrapolated to results that might be achieved with thermal ablation. Future investigations need to address this deficiency in a meaningful way to push the field forward.

Many recommendations regarding healed patients or patients with potential VLU are based on extrapolations from the data obtained from patients with active VLUs. Each specific patient condition needs focused investigation to determine what "best care" is. Several methods of great and small saphenous ablation are under investigation and may provide even less risk for the benefits provided.

Many in the venous community have reserved deep venous reconstruction for those cases in which nothing else has been successful. This treatment option has been a forgotten therapeutic alternative for a growing population of patients with deep venous insufficiency in whom nonsurgical and superficial venous intervention has been unsuccessful. Because of the ease of other interventions or a misguided assumption, there is room to reinvestigate this assumption by comparing repair of deep venous insufficiency vs outflow obstruction interventions in patients who have both conditions.

Ancillary. Ancillary measures to improve ulcer healing include adequate nutrition to provide sufficient vitamins, minerals, and protein to support the growth of granulation tissue. Whereas pentoxifylline and micronized purified flavonoid fraction, both in combination with compression therapy, have demonstrated a beneficial effect on ulcer healing, these medications are not widely used. Better understanding of the pathophysiologic mechanism of the VLU may help develop other novel systemic or local treatment. Physiotherapy is a useful ancillary measure to VLU healing as it improves calf muscle pump function and

reduces edema, but it is also not readily available. There is moderate-quality evidence that increased physical activity, improved mobility, and foot exercises decrease VLU recurrence, but more standardization is required.

Primary Prevention. Cost-effectiveness of VLU prevention is difficult to rigorously prove owing to the requirement for large patient numbers in these trials and the heterogeneous nature of CVI. Adequate compression in a compliant patient with C1-C4 disease and the use of evidence-based therapies for treatment with prevention of DVT recurrence should go a long way toward decreasing the incidence of VLU. Although much information is available to patients online and by other sources, dissemination of preventive measures to front-line physicians and advanced practice providers is critical for reaching the most patients possible at risk of VLU.

As for all clinical classes of CVI, there is a knowledge gap as to whether adequate compression and skin care or, alternatively, surgical intervention for superficial venous incompetence prevents progression to another clinical disease level, specifically from C4 to C6.

REFERENCES

1. Committee on Clinical Practice Guidelines, Institute of Medicine. Guidelines for clinical practice: From development to use. Washington, DC: National Academy Press; 1992.
2. Ruckley CV. Socio-economic impact of chronic venous insufficiency and leg ulcers. *Angiology* 1997;48:67-9.
3. Passman MA. Non-medical initiatives to decrease venous ulcer prevalence. *J Vasc Surg* 2010;52:29S-36S.
4. Tatsioni A, Balk E, O'Donnell TF Jr, Lau J. Usual care in the management of chronic wounds: A review of the recent literature. *J Am Coll Surg* 2007;205:617-24.
5. Ruckley CV, Evans CJ, Allan P, Lee AJ, Fowkes GR. Chronic venous insufficiency: Clinical and duplex correlations. The Edinburgh Vein Study of venous disorders in the general population. *J Vasc Surg* 2002;36:520-5.
6. Fischer H. Venenleiden—eine repräsentative Untersuchung in der Bundesrepublik Deutschland (Tübinger Studie). München, Germany: Urban & Schwarzenberg; 1981.
7. Jawien A, Grzela T, Ochwat A. Prevalence of chronic venous insufficiency in men and women in Poland: Multicenter cross-sectional study in 40,095 patients. *Phlebology* 2003;18:110.
8. Carpentier PH, Maricq HR, Biro C, Poncot-Makinen CO, Franco A. Prevalence, risk factors and clinical patterns of chronic venous disorders of lower limbs. A population-based study in France. *J Vasc Surg* 2004;40:650-9.
9. Rabe E, Pannier-Fischer F, Bromen K, Schuldt K, Stang A, Poncar C, et al. Bonner Venenstudie der Deutschen Gesellschaft für Phlebologie/epidemiologische Untersuchung zur Frage der Häufigkeit und Ausprägung von chronischen Venenkrankheiten in der städtischen und ländlichen Wohnbevölkerung. *Phlebologie* 2003;32:1-14.
10. McLafferty RB, Passman MA, Caprini JA, Rooke TW, Markwell SA, Lohr JM, et al. Increasing awareness about venous disease: The American Venous Forum expands the National Venous Screening Program. *J Vasc Surg* 2008;48:394-9.
11. Rhodes JM, Glociczki P, Canton LG, Rooke T, Lewis BD, Lindsey JR. Factors affecting clinical outcome following endoscopic perforator vein ablation. *Am J Surg* 1998;176:162-7.
12. Nelzen O. Leg ulcers: Economic Aspects. Cost effectiveness analysis of leg ulcers. *Phlebology* 2000;15:110-4.
13. Rippon M, Davies P, White R, Bosanquet N. The economic impact of hard-to-heal leg ulcers. *Wounds UK* 2007;3:58-69.
14. Simka M, Majewski E. The social and economic burden of venous leg ulcers: Focus on the role of micronized purified flavonoid fraction adjuvant therapy. *Am J Clin Dermatol* 2003;4:573-81.
15. Van Gent BW, Wilschut ED, Wittens CW. Management of venous ulcer disease. *BMJ* 2010;341:c6045.
16. Olin JW, Beusterien KM, Childs MB, Seavey C, McHugh L, Griffiths RI. Medical costs of treating venous stasis ulcers; evidence from a retrospective cohort study. *Vasc Med* 1999;4:1-7.
17. Ma H, O'Donnell TF Jr, Rosen NA, Iafrafi MD. The real costs of treating venous ulcers in a contemporary vascular practice [published online ahead of print June 24, 2014]. *J Vasc Surg: Venous and Lym Dis* doi: 10.1016/j.jvsv.2014.04.006.
18. O'Donnell TF, Balk EM. The need for an Intersociety Consensus Guideline for venous ulcer. *J Vasc Surg* 2011;54:83S-90S.
19. Olson JM, Raugi GJ, Nguyen VQ, et al. Guideline concordant venous ulcer care predicts healing in a tertiary care Veterans Affairs Medical Center. *Wound Repair Regen* 2009;17:666-70.
20. McGuckin M, Waterman R, Brooks J, Cherry G, Porten L, Hurley S, et al. Validation of venous leg ulcer guidelines in the United States and United Kingdom. *Am J Surg* 2002;183:132-7.
21. Nelzen O. Fifty percent reduction in venous ulcer prevalence is achievable—Swedish experience. *J Vasc Surg* 2010;52(Suppl):39S-44S.
22. Forsgren A, Nelzén O. Changes in the aetiological spectrum of leg ulcers after a broad-scale intervention in a defined geographical population in Sweden. *Eur J Vasc Endovasc Surg* 2012;44:498-503.
23. Glociczki P, Comerota AJ, Dalsing MC, Eklof BG, Gillespie DL, Glociczki ML, et al. The care of patients with varicose veins and associated chronic venous diseases: Clinical practice guidelines of the Society for Vascular Surgery and the American Venous Forum. *J Vasc Surg* 2011;53:2S-48S.
24. Meissner MH, Glociczki P, Comerota AJ, Dalsing MC, Eklof BG, Gillespie DL, et al. Early thrombus removal strategies for acute deep venous thrombosis: Clinical Practice Guidelines of the Society for Vascular Surgery and the American Venous Forum. *J Vasc Surg* 2012;55:1449-62.
25. Institute of Medicine. Clinical practice guidelines we can trust. Washington, DC: The National Academies Press; 2011.
26. Sackett DL, Rosenberg WM, Gray JA, et al. Evidence based medicine: What it is and what it isn't. *BMJ* 1996;312:71-2.
27. Meissner MH. "I enjoyed your talk, but...": Evidence-based medicine and the scientific foundation of the American Venous Forum. *J Vasc Surg* 2009;49:244-8.
28. O'Donnell TF Jr, Lau J. A systematic review of randomized controlled trials of wound dressings for chronic venous ulcer. *J Vasc Surg* 2006;44:118-25.
29. Lurie F, Kistner RL, Eklof B, et al. The structure and processes of the Pacific Vascular Symposium. *J Vasc Surg* 2010;52(Suppl):3S-7S.
30. Mauck KF, Asi N, Elraiyah TA, Undavalli C, Nabhan M, Altavar O, et al. Comparative systematic review and meta-analysis of compression modalities for the promotion of venous ulcer healing and reducing ulcer recurrence. *J Vasc Surg* 2014;60:73S-92S.
31. Mauck KF, Asi N, Undavalli C, Elraiyah TA, Nabhan M, Altavar O, et al. Systematic review and meta-analysis of surgical interventions versus conservative therapy from venous ulcers. *J Vasc Surg* 2014;60:60S-72S.
32. Guyatt G, Gutterman D, Baumann MH, Addrizzo-Harris D, Hylek EM, Phillips B, et al. Grading strength of recommendations and quality of evidence in clinical guidelines: Report from an American College of Chest Physicians task force. *Chest* 2006;129:174-81.
33. Murad MH, Montori VM, Sidawy AN, Ascher E, Meissner MH, Chaikof EL, et al. Guideline methodology of the Society for Vascular Surgery including the experience with the GRADE framework. *J Vasc Surg* 2011;53:137S-80.
34. Guyatt G, Oxman AD, Akl EA, Kunz R, Vist G, Brozek J, et al. GRADE guidelines: 1. Introduction—GRADE evidence profiles and summary of findings tables. *J Clin Epidemiol* 2011;64:383-94.
35. Glociczki P. Handbook of venous disorders: Guidelines of the American Venous Forum. 3rd ed. London: Hodder Arnold; 2009.
36. Scottish Intercollegiate Guidelines Network—update of SIGN 26. The care of patients with chronic (venous) leg ulcers. August 2012. Available at: www.sign.ac.uk/pdf/SIGN120.pdf. Accessed October 30, 2013.

37. Haute Autorité de Santé (HAS). Clinical practice guidelines. Managing venous leg ulcers excluding dressings. June 2006. Available at: www.has-sante.fr. Accessed October 30, 2013.
38. Caggiati A, Bergan JJ, Gloviczki P, Jantet G, Wendell-Smith CP, Partsch H, International Interdisciplinary Consensus Committee on Venous Anatomical Terminology. Nomenclature of the veins of the lower limbs: An international interdisciplinary consensus statement. *J Vasc Surg* 2002;36:416-22.
39. Caggiati A, Bergan JJ, Gloviczki P, Eklof B, Allegra C, Partsch H. Nomenclature of the veins of the lower limb: Extensions, refinements, and clinical application. *J Vasc Surg* 2005;41:719-24.
40. Labropoulos N, Leon M, Nicolaides AN, Giannoukas AD, Volteas N, Chan P. Superficial venous insufficiency: Correlation of anatomic extent of reflux with clinical symptoms and signs. *J Vasc Surg* 1994;20:953-8.
41. Meissner MH, Moneta G, Burnand K, Gloviczki P, Lohr JM, Lurie F, et al. The hemodynamics and diagnosis of venous disease. *J Vasc Surg* 2007;46(Suppl S):4S-24S.
42. Labropoulos N, Leon M, Nicolaides AN, Sowade O, Volteas N, Ortega F, et al. Venous reflux in patients with previous deep venous thrombosis: Correlation with ulceration and other symptoms. *J Vasc Surg* 1994;20:20-6.
43. Labropoulos N, Gasparis AP, Tassiopoulos AK. Prospective evaluation of the clinical deterioration in post-thrombotic limbs. *J Vasc Surg* 2009;50:826-30.
44. Labropoulos N, Gasparis AP, Pefanis D, Leon LR Jr, Tassiopoulos AK. Secondary chronic venous disease progresses faster than primary. *J Vasc Surg* 2009;49:704-10.
45. Eberhardt RT, Raffetto JD. Chronic venous insufficiency. *Circulation* 2005;111:2398-409.
46. Raffetto JD, Khalil RA. Mechanisms of varicose vein formation: Valve dysfunction and wall dilation. *Phlebology* 2008;23:85-98.
47. Deroo S, Deatrick KB, Henke PK. The vessel wall: A forgotten player in post thrombotic syndrome. *Thromb Haemost* 2010;104:681-92.
48. Raffetto JD. Inflammation in chronic venous ulcers. *Phlebology* 2013;28(Suppl 1):61-7.
49. Meissner MH, Manzo RA, Bergelin RO, Markel A, Strandness DE Jr. Deep venous insufficiency: The relationship between lysis and subsequent reflux. *J Vasc Surg* 1993;18:596-605.
50. Henke PK, Pearce CG, Moaveni DM, Moore AJ, Lynch EM, Longo C, et al. Targeted deletion of CCR2 impairs deep vein thrombosis resolution in a mouse model. *J Immunol* 2006;177:3388-97.
51. Lester PA, Diaz JA, Shuster KA, Henke PK, Wakefield TW, Myers DD. Inflammation and thrombosis: New insights. *Front Biosci (Schol Ed)* 2012;4:620-38.
52. Anwar MA, Georgiadis KA, Shalhoub J, Lim CS, Gohel MS, Davies AH. A review of familial, genetic, and congenital aspects of primary varicose vein disease. *Circ Cardiovasc Genet* 2012;5:460-6.
53. Cornu-Thenard A, Boivin P, Baud JM, De Vincenzi I, Carpentier PH. Importance of the familial factor in varicose disease. Clinical study of 134 families. *J Dermatol Surg Oncol* 1994;20:318-26.
54. Zamboni P, Gemmati D. Clinical implications of gene polymorphisms in venous leg ulcer: A model in tissue injury and reparative process. *Thromb Haemost* 2007;98:131-7.
55. Zamboni P, Tognazzo S, Izzo M, Pancaldi F, Scapoli GL, Liboni A, et al. Hemochromatosis C282Y gene mutation increases the risk of venous leg ulceration. *J Vasc Surg* 2005;42:309-14.
56. Tognazzo S, Gemmati D, Palazzo A, Catozzi L, Carandina S, Legnaro A, et al. Prognostic role of factor XIII gene variants in nonhealing venous leg ulcers. *J Vasc Surg* 2006;44:815-9.
57. Zamboni P, De Mattei M, Ongaro A, Fogato L, Carandina S, De Palma M, et al. Factor XIII contrasts the effects of metalloproteinases in human dermal fibroblast cultured cells. *Vasc Endovasc Surg* 2004;38:431-8.
58. Gemmati D, Tognazzo S, Catozzi L, Federici F, De Palma M, Gianesini S, et al. Influence of gene polymorphisms in ulcer healing process after superficial venous surgery. *J Vasc Surg* 2006;44:554-62.
59. Schmid-Shonbein GW, Takase S, Bergan JJ. New advances in the understanding of the pathophysiology of chronic venous insufficiency. *Angiology* 2001;52(Suppl 1):S27-34.
60. Bergan JJ, Schmid-Shonbein GW, Coleridge Smith PD, Nicolaides AN, Boisseau MR, Eklof B. Chronic venous disease. *N Engl J Med* 2006;355:488-98.
61. Chen YS, Lu MJ, Huang HS, Ma MC. Mechanosensitive transient receptor potential vanilloid type 1 channels contribute to vascular remodeling of rat fistula veins. *J Vasc Surg* 2010;52:1310-20.
62. Ono T, Bergan JJ, Schmid-Schönbein GW, Takase S. Monocyte infiltration into venous valves. *J Vasc Surg* 1998;27:158-66.
63. Takase S, Pascarella L, Lerond L, Bergan JJ, Schmid-Schönbein GW. Venous hypertension, inflammation and valve remodeling. *Eur J Vasc Endovasc Surg* 2004;28:484-93.
64. Mannello F, Raffetto JD. Matrix metalloproteinase activity and glycosaminoglycans in chronic venous disease: The linkage among cell biology, pathology and translational research. *Am J Transl Res* 2011;3:149-58.
65. Mannello F, Medda V, Ligi D, Raffetto JD. Glycosaminoglycan sulodexide inhibition of MMP-9 gelatinase secretion and activity: Possible pharmacological role against collagen degradation in vascular chronic diseases. *Curr Vasc Pharmacol* 2013;11:354-65.
66. Raffetto JD, Qiao X, Koledova VV, Khalil RA. Prolonged increases in vein wall tension increase matrix metalloproteinases and decrease constriction in rat vena cava: Potential implications in varicose veins. *J Vasc Surg* 2008;48:447-56.
67. Raffetto JD, Ross RL, Khalil RA. Matrix metalloproteinase 2—induced venous dilation via hyperpolarization and activation of K⁺ channels: Relevance to varicose vein formation. *J Vasc Surg* 2007;45:373-80.
68. Raffetto JD, Barros YV, Wells AK, Khalil RA. MMP-2 induced vein relaxation via inhibition of [Ca²⁺]_i-dependent mechanisms of venous smooth muscle contraction. Role of RGD peptides. *J Surg Res* 2010;159:755-64.
69. Lim CS, Qiao X, Reslan OM, Xia Y, Raffetto JD, Paleolog E, et al. Prolonged mechanical stretch is associated with upregulation of hypoxia-inducible factors and reduced contraction in rat inferior vena cava. *J Vasc Surg* 2011;53:764-73.
70. Lim CS, Kiriakidis S, Paleolog EM, Davies AH. Increased activation of the hypoxia-inducible factor pathway in varicose veins. *J Vasc Surg* 2012;55:1427-39.
71. Trengove NJ, Bielefeldt-Ohmann H, Stacey MC. Mitogenic activity and cytokine levels in non-healing and healing chronic leg ulcers. *Wound Repair Regen* 2000;8:13-25.
72. Tian YW, Stacey MC. Cytokines and growth factors in keratinocytes and sweat glands in chronic venous leg ulcers. An immunohistochemical study. *Wound Repair Regen* 2003;11:316-25.
73. Gohel MS, Windhaber RA, Tarlton JF, Whyman MR, Poskitt KR. The relationship between cytokine concentrations and wound healing in chronic venous ulceration. *J Vasc Surg* 2008;48:1272-7.
74. Wysocki AB, Staiano-Coico L, Grinnell F. Wound fluid from chronic leg ulcers contains elevated levels of metalloproteinases MMP-2 and MMP-9. *J Invest Dermatol* 1993;101:64-8.
75. Weckroth M, Vaheiri A, Lauharanta J, Sorsa T, Kontinen YT. Matrix metalloproteinases, gelatinase and collagenase in chronic leg ulcers. *J Invest Dermatol* 1996;106:1119-24.
76. Herouy Y, May AE, Pomschlegel G, Stetter C, Grenz H, Preissner KT, et al. Lipodermatosclerosis is characterized by elevated expression and activation of matrix metalloproteinases. Implications for venous ulcer formation. *J Invest Dermatol* 1998;111:822-7.
77. Herouy Y, Trefzer D, Hellstern MO, Stark GB, Vanscheidt W, Schöpf E, et al. Plasminogen activation in venous leg ulcers. *Br J Dermatol* 2000;143:930-6.
78. Norgauer J, Hildenbrand T, Idzko M, Panther E, Bandemir E, Hartmann M, et al. Elevated expression of extracellular matrix metalloproteinase inducer (CD147) and membrane-type matrix metalloproteinases in venous leg ulcers. *Br J Dermatol* 2002;147:1180-6.
79. Mwaure B, Mahendran B, Hynes N, Defreitas D, Avalos G, Adegbola T, et al. The impact of differential expression of extracellular

- matrix metalloproteinase inducer, matrix metalloproteinase-2, tissue inhibitor of matrix metalloproteinase-2 and PDGF-AA on the chronicity of venous leg ulcers. *Eur J Vasc Endovasc Surg* 2006;31:306-10.
80. Meyer FJ, Burnand KG, Abisi S, Tekoppele JM, van Els B, Smith A. Effect of collagen turnover and matrix metalloproteinase activity on healing of venous leg ulcers. *Br J Surg* 2008;95:319-25.
 81. Raffetto JD, Vasquez R, Goodwin DG, Menzoian JO. Mitogen-activated protein kinase pathway regulates cell proliferation in venous ulcer fibroblasts. *Vasc Endovascular Surg* 2006;40:59-66.
 82. Raffetto JD, Gram CH, Overman KC, Menzoian JO. Mitogen-activated protein kinase p38 pathway in venous ulcer fibroblasts. *Vasc Endovascular Surg* 2008;42:367-74.
 83. Beidler SK, Douillet CD, Berndt DF, Keagy BA, Rich PB, Marston WA. Inflammatory cytokine levels in chronic venous insufficiency ulcer tissue before and after compression therapy. *J Vasc Surg* 2009;49:1013-20.
 84. Pappas PJ, DeFouw DO, Venezio LM, Gorti R, Padberg FT Jr, Silva MB Jr, et al. Morphometric assessment of the dermal microcirculation in patients with chronic venous insufficiency. *J Vasc Surg* 1997;26:784-95.
 85. Sansilvestri-Morel P, Rupin A, Badier-Commander C, Kern P, Fabiani JN, Verbeuren TJ, et al. Imbalance in the synthesis of collagen type I and collagen type III in smooth muscle cells derived from human varicose veins. *J Vasc Res* 2001;38:560-8.
 86. Sansilvestri-Morel P, Rupin A, Jaisson S, Fabiani JN, Verbeuren TJ, Vanhoutte PM. Synthesis of collagen is dysregulated in cultured fibroblasts derived from skin of subjects with varicose veins as it is in venous smooth muscle cells. *Circulation* 2002;106:479-83.
 87. Sansilvestri-Morel P, Rupin A, Jullien ND, Lembrez N, Mestries-Dubois P, Fabiani JN, et al. Decreased production of collagen type III in cultured smooth muscle cells from varicose vein patients is due to a degradation by MMPs: Possible implication of MMP-3. *J Vasc Res* 2005;42:388-98.
 88. Vincent JR, Jones GT, Hill GB, van Rij AM. Failure of microvenous valves in small superficial veins is a key to the skin changes of venous insufficiency. *J Vasc Surg* 2011;54(Suppl):62S-9S.
 89. Anwar MA, Shalhoub J, Vorkas PA, Lim CS, Want EJ, Nicholson JK, et al. In-vitro identification of distinctive metabolic signatures of intact varicose vein tissue via magic angle spinning nuclear magnetic resonance spectroscopy. *Eur J Vasc Endovasc Surg* 2012;44:442-50.
 90. Lim CS, Davies AH. Pathogenesis of primary varicose veins. *Br J Surg* 2009;96:1231-42.
 91. Lim CS, Gohel MS, Shepherd AC, Paleolog E, Davies AH. Venous hypoxia: A poorly studied etiological factor of varicose veins. *J Vasc Res* 2011;48:185-94.
 92. Bradbury A, Ruckley CV. Clinical presentation and assessment of patients with venous disease. In: Gloviczki P, editor. *Handbook of venous disorders: Guidelines of the American Venous Forum*. 3rd ed. London: Hodder Arnold; 2009. p. 331-41.
 93. Bradbury AW, Evans CJ, Allan PL, Lee A, Vaughan Ruckley C, Fowkes FGR. What are the symptoms of varicose veins? Edinburgh vein study cross sectional population survey. *BMJ* 1999;318:353-6.
 94. Abbade LP, Lastória S, Rollo Hde A. Venous ulcer: Clinical characteristics and risk factors. *Int J Dermatol* 2011;50:405-11.
 95. Langer RD, Ho E, Denenberg JO, Fronck A, Allison M, Criqui MH, et al. Relationships between symptoms and venous disease: The San Diego population study. *Arch Intern Med* 2005;165:1420-4.
 96. Jiang P, van Rij AM, Christie R, Hill G, Solomon C, Thomson I. Recurrent varicose veins: Patterns of reflux and clinical severity. *Cardiovasc Surg* 1999;7:332-9.
 97. Nelzén O, Bergqvist D, Lindhagen A. Venous and non-venous leg ulcers: Clinical history and appearance in a population study. *Br J Surg* 1994;81:182-7.
 98. Korber A, Klode J, Al-Benna S, Wax C, Schadendorf D, Steinstraesser L, et al. Etiology of chronic leg ulcers in 31,619 patients in Germany analyzed by an expert survey. *J Dtsch Dermatol Ges* 2011;9:116-21.
 99. Pannier F, Rabe E. Differential diagnosis of leg ulcers. *Phlebology* 2013;28(Suppl 1):55-60.
 100. Labropoulos N, Manalo D, Patel NP, Tionson J, Pryor L, Giannoukas AD, et al. Uncommon leg ulcers in the lower extremity. *J Vasc Surg* 2007;45:568-73.
 101. Dissemond J, Korber A, Grabbe S. Differential diagnosis of leg ulcers. *J Dtsch Dermatol Ges* 2006;4:627-34.
 102. Stacey MC, Burnand KG, Layer GT, Pattison M, Browse NL. Measurement of the healing of venous ulcers. *Aust N Z J Surg* 1991;61:844-8.
 103. Mayrovitz HN, Soontupe LB. Wound areas by computerized planimetry of digital images: Accuracy and reliability. *Adv Skin Wound Care* 2009;22:222-9.
 104. Kecej Leskovec N, Perme MP, Jezersek M, Mozina J, Pavlović MD, et al. Initial healing rates as predictive factors of venous ulcer healing: The use of a laser-based three-dimensional ulcer measurement. *Wound Repair Regen* 2008;16:507-12.
 105. Kantor J, Margolis DJ. A multicentre study of percentage change in venous leg ulcer area as a prognostic index of healing at 24 weeks. *Br J Dermatol* 2000;142:960-4.
 106. Jessup RL. What is the best method for assessing the rate of wound healing? A comparison of 3 mathematical formulas. *Adv Skin Wound Care* 2006;19:138-47.
 107. Gorin DR, Cordts PR, LaMorte WW, Manzoian JO. The influence of wound geometry on the measurement of wound healing rates in clinical trials. *J Vasc Surg* 1996;23:524-8.
 108. Lazarus GS, Cooper DM, Knighton DR, Margolis DJ, Pecoraro RE, Rodeheaver G, et al. Definitions and guidelines for assessment of wounds and evaluation of healing. *Arch Dermatol* 1994;130:489-93.
 109. Cardinal M, Eisenbud DE, Phillips T, Harding K. Early healing rates and wound area measurements are reliable predictors of later complete wound closure. *Wound Repair Regen* 2008;16:19-22.
 110. Hill DP, Poore S, Wilson J, Robson MC, Cherry GW. Initial healing rates of venous ulcers: Are they useful as predictors of healing? *Am J Surg* 2004;188:22-5.
 111. Keast DH, Bowering K, Evans AW, Mackean GL, Burrows C, D'Souza L. MEASURE: A proposed assessment framework for developing best practice recommendations for wound assessment. *Wound Rep Regen* 2004;12:S1-17.
 112. Ratliff CR, Rodeheaver GT. Use of the PUSH tool to measure venous ulcer healing. *Ostomy Wound Manage* 2005;51:58-60, 62-3.
 113. Steed DL, Hill DP, Woodske ME, Payne WG, Robson MC. Wound-healing trajectories as outcome measures of venous stasis ulcer treatment. *Int Wound J* 2006;3:40-7.
 114. Hansson C, Hoborn J, Moller A, Swanbeck G. The microbial flora in venous leg ulcers without clinical signs of infection. Repeated culture using a validated standardised microbiological technique. *Acta Derm Venereol* 1995;75:24-30.
 115. Dowd SE, Sun Y, Secor PR, Rhoads DD, Wolcott BM, James GA, et al. Survey of bacterial diversity in chronic wounds using pyrosequencing, DGGE, and full ribosome shotgun sequencing. *BMC Microbiol* 2008;8:43.
 116. Hill KE, Davies CE, Wilson MJ, Stephens P, Harding KG, Thomas DW. Molecular analysis of the microflora in chronic venous leg ulceration. *J Med Microbiol* 2003;52:365-9.
 117. Gjodsbol K, Christensen JJ, Karlsmark T, Jorgensen B, Klein BM, Kroghfelt KA. Multiple bacterial species reside in chronic wounds: A longitudinal study. *Int Wound J* 2006;3:225-31.
 118. Moore K, Hall V, Paull A, Morris T, Brown S, McCulloch D, et al. Surface bacteriology of venous leg ulcers and healing outcome. *J Clin Pathol* 2010;63:830-4.
 119. Rhoads DD, Wolcott RD, Sun Y, Dowd SE. Comparison of culture and molecular identification of bacteria in chronic wounds. *Int J Mol Sci* 2012;13:2535-50.
 120. Wolcott RD, Cox SB, Dowd SE. Healing and healing rates of chronic wounds in the age of molecular pathogen diagnostics. *J Wound Care* 2010;19:272-8.
 121. Gjodsbol K, Skindersoe ME, Christensen JJ, Karlsmark T, Jorgensen B, Jensen AM, et al. No need for biopsies: Comparison of three sample techniques for wound microbiota determination. *Int Wound J* 2012;9:295-302.

122. Davies CE, Hill KE, Newcombe RG, Stephens P, Wilson MJ, Harding KG, et al. A prospective study of the microbiology of chronic venous leg ulcers to reevaluate predictive value of tissue biopsies and swabs. *Wound Repair Regen* 2007;15:17-22.
123. Cooper RA, Ameen H, Price P, McCulloch DA, Harding KG. A clinical investigation into the microbiological status of 'locally infected' leg ulcers. *Int Wound J* 2009;6:453-62.
124. Angel DE, Lloyd P, Carville K, Santamaria N. The clinical efficacy of two semi-quantitative wound-swabbing techniques in identifying the causative organisms in infected cutaneous wounds. *Int Wound J* 2011;8:176-85.
125. Levine NS, Lindberg RB, Mason AD Jr, Pruitt BA Jr. The quantitative swab culture and smear: A quick method for determining the number of viable aerobic bacteria in open wounds. *J Trauma* 1976;16:89-94.
126. Yang D, Morrison BD, Vandongen YK, Singh A, Stacey MC. Malignancy in chronic leg ulcers. *Med J Aust* 1996;164:718-20.
127. Senet P, Combemale P, Debure C, Baudot N, Macher L, Aout M, et al. Angio-Dermatology Group of the French Society of Dermatology. Malignancy and chronic leg ulcers: The value of systematic wound biopsies: A prospective, multicenter, cross-sectional study. *Arch Dermatol* 2012;148:704-8.
128. Stanford R, Lowell D, Raju R, Arya A. Marjolin's ulcer of the leg secondary to nonhealing chronic venous stasis ulcer. *J Foot Ankle Surg* 2012;51:475-8.
129. Beidler SK, Douillet CD, Berndt DF, Keagy BA, Rich PB, Marston WA. Multiplexed analysis of matrix metalloproteinases in leg ulcer tissue of patients with chronic venous insufficiency before and after compression therapy. *Wound Repair Regen* 2008;16:642-8.
130. Panuncialman J, Hammerman S, Carson P, Falanga V. Wound edge biopsy sites in chronic wounds heal rapidly and do not result in delayed overall healing of the wounds. *Wound Repair Regen* 2010;18:21-5.
131. Mackenzie RK, Ludlam CA, Ruckley CV, Allan PL, Burns P, Bradbury AW. The prevalence of thrombophilia in patients with chronic venous leg ulceration. *J Vasc Surg* 2002;35:718-22.
132. Darvall KA, Sam RC, Adam DJ, Silverman SH, Fegan CD, Bradbury AW. Higher prevalence of thrombophilia in patients with varicose veins and venous ulcers than controls. *J Vasc Surg* 2009;49:1235-41.
133. Brandt HR, de Lorenzo Messina MC, Hirayama JT, Belda W Jr, Benabou JE, Criado PR. Prevalence of thrombophilia associated with leg ulcers. *Br J Dermatol* 2009;160:202-3.
134. Calistru AM, Baudrier T, Gonvalves L, Azevedo F. Thrombophilia in venous leg ulcers: A comparative study in early and later onset. *Indian J Dermatol Venereol Leprol* 2012;78:406.
135. Wiszniewski A, Bykowska K, Bilski R, Jaškowiak W, Proniewski J. Prevalence rate for inherited thrombophilia in patients with chronic and recurrent venous leg ulceration. *Wound Repair Regen* 2011;19:552-8.
136. Bradbury AW, MacKenzie RK, Burns P, Fegan C. Thrombophilia and chronic venous ulceration. *Eur J Vasc Endovasc Surg* 2002;24:97-104.
137. Spentzouris G, Labropoulos N. The evaluation of lower-extremity ulcers. *Semin Intervent Radiol* 2009;26:286-95.
138. Norgren L, Hiatt WR, Dormandy JA, Nehler MR, Harris KA, Fowkes FG; TASC II Working Group. Inter-Society Consensus for the Management of Peripheral Arterial Disease (TASC II). *J Vasc Surg* 2007;45(Suppl S):S5-67.
139. Andersson E, Hansson C, Swanbeck G. Leg and foot ulcer prevalence and investigation of the peripheral arterial and venous circulation in a randomised elderly population. An epidemiological survey and clinical investigation. *Acta Derm Venereol* 1993;73:57-61.
140. Callam MJ, Harper DR, Dale JJ, Ruckley CV. Chronic ulcer of the leg: Clinical history. *Br Med J Clin Res Ed* 1987;294:1389-91.
141. Georgopoulos S, Kouvelos GN, Koutsoumpelis A, Bakoyiannis C, Lympieri M, Klonaris C, et al. The effect of revascularization procedures on healing of mixed arterial and venous leg ulcers. *Int Angiol* 2013;32:368-74.
142. Iabichella ML, Melillo E, Mosti G. A review of microvascular measurements in wound healing. *Int J Low Extrem Wounds* 2006;5:181-99.
143. Gschwandtner ME, Ehringer H. Microcirculation in chronic venous insufficiency. *Vasc Med* 2001;6:169-79.
144. Ambrozy E, Waczulikova I, Willfort-Ehringer A, Ehringer H, Koppensteiner R, Gschwandtner ME. Microcirculation in mixed arterial/venous ulcers and the surrounding skin: Clinical study using a laser Doppler perfusion imager and capillary microscopy. *Wound Repair Regen* 2009;17:19-24.
145. McMullin GM, Smith C. An evaluation of Doppler ultrasound and photoplethysmography in the investigation of venous insufficiency. *Aust N Z J Surg* 1992;62:270-5.
146. Rautio T, Perala J, Biancari F, Wiik H, Ohtonen P, Haukipuro K, et al. Accuracy of hand-held Doppler in planning the operation for primary varicose veins. *Eur J Vasc Endovasc Surg* 2002;24:450-5.
147. Haenen JH, van Langen H, Janssen MC, Wollersheim H, van't hof MA, van Asten WN, et al. Venous duplex scanning of the leg: Range, variability and reproducibility. *Clin Sci* 1999;96:271-7.
148. Abai B, Labropoulos N. Duplex ultrasound scanning for chronic venous obstruction and valvular incompetence. In: Glociczki P, editor. *Handbook of venous disorders: Guidelines of the American Venous Forum*. 3rd ed. London: Hodder Arnold; 2009. p. 142-55.
149. Sarin S, Sommerville K, Farrah J, Scurr JH, Coleridge Smith PD. Duplex ultrasonography for assessment of venous valvular function of the lower limb. *Br J Surg* 1994;81:1591-5.
150. Intersocietal Commission for the Accreditation of Vascular Laboratories. The complete ICAVL standards for accreditation in noninvasive vascular testing. Available at: http://www.icavl.org/icavl/standards/2010_ICAVL_Standards.pdf2010.
151. Masuda EM, Kistner RL, Eklof B. Prospective study of duplex scanning for venous reflux: Comparison of Valsalva and pneumatic cuff techniques in the reverse Trendelenburg and standing positions. *J Vasc Surg* 1994;20:711-20.
152. Markel A, Meissner MH, Manzo RA, Bergelin RO, Strandness DE. A comparison of the cuff deflation method with Valsalva's maneuver and limb compression in detecting venous valvular reflux. *Arch Surg* 1994;129:701-5.
153. Labropoulos N, Tiongsong J, Pryor L, Tassiopoulos AK, Kang SS, Ashraf Mansour M, et al. Definition of venous reflux in lower-extremity veins. *J Vasc Surg* 2003;38:793-8.
154. Lurie F, Comerota A, Eklof B, Kistner RL, Labropoulos N, Lohr J, et al. Multicenter assessment of venous reflux by duplex ultrasound. *J Vasc Surg* 2012;55:437-45.
155. Glociczki P, Baker WH. New insights into perforator vein incompetence. *Eur J Vasc Endovasc Surg* 1999;18:228-34.
156. Sandri JL, Barros FS, Pontes S, Jacques C, Salles-Cunha SX. Diameter reflux relationship in perforating veins of patients with varicose veins. *J Vasc Surg* 1999;30:867-74.
157. Labropoulos N, Patel PJ, Tiongsong JE, Pryor L, Leon LR Jr, Tassiopoulos AK. Patterns of venous reflux and obstruction in patients with skin damage due to chronic venous disease. *Vasc Endovasc Surg* 2007;41:33-40.
158. Yamaki T, Nozaki M, Sasaki K. Color duplex ultrasound in assessment of primary venous leg ulceration. *Dermatol Surg* 1998;24:1124-8.
159. Labropoulos N, Leon M, Geroulakos G, Volteas N, Chan P, Nicolaides AN. Venous hemodynamic abnormalities in patients with leg ulceration. *Am J Surg* 1995;169:572-4.
160. Labropoulos N, Giannoukas AD, Nicolaides AN, Ramaswami G, Leon M, Burke P. New insights into the pathophysiologic condition of venous ulceration with color-flow duplex imaging: Implications for treatment. *J Vasc Surg* 1995;22:45-50.
161. Hanrahan LM, Araki CT, Rodriguez AA, Kechejian GJ, LaMorte WW, Menzoian JO, et al. Distribution of valvular incompetence in patients with venous stasis ulceration. *J Vasc Surg* 1991;13:805-11.
162. Obermayer A, Garzon K. Identifying the source of superficial reflux in venous leg ulcers using duplex ultrasound. *J Vasc Surg* 2010;52:1255-61.
163. Labropoulos N, Giannoukas AD, Nicolaides AN, Veller M, Leon M, Volteas N, et al. The role of venous reflux and calf muscle pump function in nonthrombotic chronic venous insufficiency. Correlation with severity of signs and symptoms. *Arch Surg* 1996;131:403-6.

164. Struckmann JR. Assessment of the venous muscle pump function by ambulatory strain gauge plethysmography. Methodological and clinical aspects. *Dan Med Bull* 1993;40:460-77.
165. Criado E, Farber MA, Marston WA, Daniel PF, Burnham CB, Keagy BA, et al. The role of air plethysmography in the diagnosis of chronic venous insufficiency. *J Vasc Surg* 1998;27:660-70.
166. Green S, Thorp R, Reeder EJ. Venous occlusion plethysmography versus Doppler ultrasound in the assessment of leg blood flow during calf exercise. *Eur J Appl Physiol* 2011;111:1889-900.
167. Lurie F, Rooke TW. Evaluation of venous function by indirect noninvasive testing (plethysmography). In: Gloviczki P, editor. *Handbook of venous disorders: Guidelines of the American Venous Forum*. 3rd ed. London: Hodder Arnold; 2009. p. 156-9.
168. Weingarten MS, Czeredarczuk M, Scovell S, Branas CC, Mignogna GM, Wolfarth CC Jr. A correlation of air plethysmography and color flow-assisted duplex scanning in the quantification of chronic venous insufficiency. *J Vasc Surg* 1996;24:750-4.
169. Rhodes JM, Gloviczki P, Canton L, Heaser TV, Rooke TW. Endoscopic perforator vein division with ablation of superficial reflux improves venous hemodynamics. *J Vasc Surg* 1998;28:839-47.
170. Park UJ, Yun WS, Lee KB, Rho YN, Kim YW, Joh JH, et al. Analysis of the postoperative hemodynamic changes in varicose vein surgery using air plethysmography. *J Vasc Surg* 2010;51:634-8.
171. Padberg FT, Pappas PJ, Araki CT, Back TL, Hobson RW 2nd. Hemodynamic and clinical improvement after superficial ablation in primary combined venous insufficiency with ulceration. *J Vasc Surg* 1996;24:711-8.
172. Owens LV, Farber MA, Young ML, Carlin RE, Criado-Pallares E, Passman MA, et al. The value of air plethysmography in predicting clinical outcome after surgical treatment of chronic venous insufficiency. *J Vasc Surg* 2000;32:961-8.
173. Raju S, Neglen P. High prevalence of nonthrombotic iliac vein lesions in chronic venous disease: A permissive role in pathogenicity. *J Vasc Surg* 2006;44:136-44.
174. Lin EP, Bhatt S, Rubens D, Dogra VS. The importance of monophasic Doppler waveforms in the common femoral vein: A retrospective study. *J Ultrasound Med* 2007;26:885-91.
175. Labropoulos N, Borge M, Pierce K, Pappas PJ. Criteria for defining significant central venous stenosis with duplex ultrasound. *J Vasc Surg* 2007;46:101-7.
176. Kalodiki E, Calahoras LS, Delis KT, Zouzas CP, Nicolaides AN. Air plethysmography: The answer in detecting past deep venous thrombosis. *J Vasc Surg* 2001;32:715-20.
177. Chung JW, Yoon CJ, Jung HC, Kim HC, Lee W, Kim YI, et al. Acute iliofemoral deep vein thrombosis: Evaluation of underlying anatomic abnormality by spiral CT venography. *J Vasc Interv Radiol* 2004;15:249-56.
178. Oguzkurt L, Ozkan U, Ulsan S, Koc Z, Tercan F. Compression of the left common iliac vein in asymptomatic subjects and patients with left iliofemoral deep vein thrombosis. *J Vasc Interv Radiol* 2008;19:366-70.
179. Wolpert LM, Rahmani O, Stein B, Gallagher JJ, Drezner AD. Magnetic resonance venography in the diagnosis and management of May-Thurner syndrome. *Vasc Endovascular Surg* 2002;36:51-7.
180. Marston W, Fish D, Unger J, Keagy B. Incidence of and risk factors for iliofemoral venous obstruction in patients with active or healed venous leg ulcers. *J Vasc Surg* 2011;53:1303-8.
181. Neglen P, Raju S. Intravascular ultrasound scan evaluation of the obstructed vein. *J Vasc Surg* 2002;35:694-700.
182. Forauer AR, Gemmete JJ, Dasika NL, Cho KJ, Williams DM. Intravascular ultrasound in the diagnosis and treatment of iliac vein compression (May-Thurner) syndrome. *J Vasc Interv Radiol* 2002;13:523-7.
183. Raju S, Hollis K, Neglen P. Obstructive lesions of the inferior vena cava: Clinical features and endovenous treatment. *J Vasc Surg* 2006;44:820-7.
184. Porter JM, Moneta GL. International Consensus Committee on Chronic Venous Disease. Reporting standards in venous disease: An update. *J Vasc Surg* 1995;21:635-45.
185. Nicolaides A, Bergan JJ, Eklof B, Kistner RL, Moneta G. Ad Hoc Committee of the American Venous Forum. Classification and grading of chronic venous disease in the lower limbs: A consensus statement. In: Gloviczki P, Yao JST, editors. *Handbook of venous disorders: Guidelines of the American Venous Forum*. London: Chapman & Hall Medical; 1996. p. 652-60.
186. Eklof B, Rutherford RB, Bergan JJ, Carpentier PH, Gloviczki P, Kistner RL, et al. Revision of the CEAP classification for chronic venous disorders: Consensus statement. *J Vasc Surg* 2004;40:1248-52.
187. Meissner MH, Natiello C, Nicholls SC. Performance characteristics of the venous clinical severity score. *J Vasc Surg* 2002;36:889-95.
188. Ricci MA, Emmerich J, Callas PW, Rosendaal FR, Stanley AC, Naud S, et al. Evaluating chronic venous disease with a new venous severity scoring system. *J Vasc Surg* 2003;38:909-15.
189. Gillet JL, Perrin MR, Allaert FA. Clinical presentation and venous severity scoring of patients with extended deep axial venous reflux. *J Vasc Surg* 2006;44:588-94.
190. Kakkos SK, Rivera MA, Matsagas MI, Lazarides MK, Robless P, Belcaro G, et al. Validation of the new venous severity scoring system in varicose vein surgery. *J Vasc Surg* 2003;38:224-8.
191. Passman MA, McLafferty RB, Lentz MF, Nagre SB, Iafrafi MD, Bohannon WT, et al. Validation of Venous Clinical Severity Score (VCSS) with other venous severity assessment tools from the American Venous Forum, National Venous Screening Program. *J Vasc Surg* 2011;54(Suppl):2S-9S.
192. Marston WA, Vasquez MA, Lurie F, Wakefield TW, Rabe E, Shortell CK, et al. Multicenter assessment of the repeatability and reproducibility of the revised Venous Clinical Severity Score (rVCSS). *J Vasc Surg Venous Lymphat Disord* 2013;1:219-24.
193. Vasquez MA, Wang J, Mahathanaruk M, Buczkowski G, Sprehe E, Doslouglu HH, et al. The utility of the Venous Clinical Severity Score in 682 limbs treated by radiofrequency saphenous vein ablation. *J Vasc Surg* 2007;45:1008-14.
194. Jayaraj A, Meissner MH. A comparison of Villalta-Prandoni scale and venous clinical severity score in the assessment of post thrombotic syndrome. *Ann Vasc Surg* 2014;28:313-7.
195. Villalta S, Bagatella P, Piccioli A, Lensing AW, Prins MH, Prandoni P. Assessment of validity and reproducibility of a clinical scale for the postthrombotic syndrome. [abstract]. *Haemostasis* 1994;24:158a.
196. Ginsberg JS, Turkstra F, Buller HR, MacKinnon B, Magier D, Hirsh J. Postthrombotic syndrome after hip or knee arthroplasty: A cross-sectional study. *Arch Intern Med* 2000;160:669-72.
197. Brandjes DP, Buller HR, Heijboer H, Huisman MV, de Rijk M, Jagt H, et al. Randomised trial of effect of compression stockings in patients with symptomatic proximal-vein thrombosis. *Lancet* 1997;349:759-62.
198. Widmer L, Stathelin H, Nissen C. Venen-, Arterien-, Krankheiten, koronare Herzkrankheit bei Berufstätigen. Bern: Verlag Hans Huber; 1981.
199. Galanaud JP, Holcroft CA, Rodger MA, Kovacs MJ, Betancourt MT, Wells PS, et al. Comparison of the Villalta post-thrombotic syndrome score in the ipsilateral vs. contralateral leg after a first unprovoked deep vein thrombosis. *J Thromb Haemost* 2012;10:1036-42.
200. Kahn SR, Hirsch A, Shrier I. Effect of postthrombotic syndrome on health-related quality of life after deep venous thrombosis. *Arch Intern Med* 2002;162:1144-8.
201. Rodger MA, Kahn SR, Le Gal G, Solymoss S, Chagnon I, Anderson DR, et al. Inter-observer reliability of measures to assess the post-thrombotic syndrome. *Thromb Haemost* 2008;100:164-6.
202. Kolbach DN, Neumann HA, Prins MH. Definition of the post-thrombotic syndrome, differences between existing classifications. *Eur J Vasc Endovasc Surg* 2005;30:404-14.
203. Kahn SR, Desmarais S, Ducruet T, Arsenault L, Ginsberg JS. Comparison of the Villalta and Ginsberg clinical scales to diagnose the post-thrombotic syndrome: Correlation with patient-reported disease burden and venous valvular reflux. *J Thromb Haemost* 2006;4:907-8.
204. Lamping DL, Schroter S, Kurz X, Kahn SR, Abenheim L. Evaluating outcomes in chronic venous disorders of the leg: Development of a scientifically rigorous patient-reported measure of symptoms and quality of life. *J Vasc Surg* 2003;37:410-9.

205. Soosainathan A, Moore HM, Gohel MS, Davies AH. Scoring systems for the post-thrombotic syndrome. *J Vasc Surg* 2013;57:254-61.
206. Kahn SR, Partsch H, Vedantham S, Prandoni P, Kearon C. Subcommittee on Control of Anticoagulation of the Scientific and Standardization Committee of the International Society on Thrombosis and Haemostasis. Definition of post-thrombotic syndrome of the leg for use in clinical investigations: A recommendation for standardization. *J Thromb Haemost* 2009;7:879-83.
207. Baker DM, Turnbull NB, Pearson JC, Makin GS. How successful is varicose vein surgery? A patient outcome study following varicose vein surgery using the SF-36 Health Assessment Questionnaire. *Eur J Vasc Endovasc Surg* 1995;9:299-304.
208. Garratt AM, Ruta DA, Abdalla MI, Russell IT. SF 36 health survey questionnaire: II. Responsiveness to changes in health status in four common clinical conditions. *Qual Health Care* 1994;3:186-92.
209. Davies AH, Rudarakanchana N. Quality of life and outcome assessment in patients with varicose veins. In: Davies AH, Lees TA, Lane IF, editors. *Venous disease simplified*. Shropshire, UK: TFM Publishing Ltd; 2006.
210. Vasquez MA, Munschauer CE. Venous Clinical Severity Score and quality-of-life assessment tools: Application to vein practice. *Phlebology* 2008;23:259-75.
211. Franks PJ, Moffatt CJ. Health related quality of life in patients with venous ulceration: Use of the Nottingham health profile. *Qual Life Res* 2001;10:693-700.
212. Wiebe S, Guyatt G, Weaver B, Matijevic S, Sidwell C. Comparative responsiveness of generic and specific quality-of-life instruments. *J Clin Epidemiol* 2003;56:52-60.
213. Launois R, Mansilha A, Jantet G. International psychometric validation of the Chronic Venous Disease quality of life Questionnaire (CIVIQ-20). *Eur J Vasc Endovasc Surg* 2010;40:783-9.
214. Kahn SR, M'LAN CE, Lamping DL, Kurz X, Berard A, Abenham LA, et al. Relationship between clinical classification of chronic venous disease and patient-reported quality of life: Results from an international cohort study. *J Vasc Surg* 2004;39:823-8.
215. Rutherford RB, Moneta GL, Padberg FT Jr, Meissner MH. Outcome assessment in chronic venous disease. In: Gloviczki P, editor. *Handbook of venous disorders: Guidelines of the American Venous Forum*. 3rd ed. London: Hodder Arnold; 2009. p. 684-93.
216. Kundu S, Lurie F, Millward SF, Padberg F Jr, Vedantham S, Elias S, et al. Recommended reporting standards for endovenous ablation for the treatment of venous insufficiency: Joint statement of the American Venous Forum and the Society of Interventional Radiology. *J Vasc Surg* 2007;46:582-9.
217. United States Department of Health and Human Services, Food and Drug Administration. *Guidance for Industry: Chronic cutaneous ulcer and burn wounds—developing products for treatment*. June 2006. Available at: <http://www.fda.gov/downloads/Drugs/GuidanceComplianceRegulatoryInformation/Guidances/UCM071324.pdf>
218. Romanelli M, Dini V, Barbanera S, Bertone MS. Evaluation of the efficacy and tolerability of a solution containing propyl betaine and polihexanide for wound irrigation. *Skin Pharmacol Physiol* 2010;23:41-4.
219. Rodeheaver GT, Kurtz L, Kircher BJ, Edlich RF. Pluronic F-68: A promising new skin wound cleanser. *Ann Emerg Med* 1980;9:572-6.
220. Rodeheaver GT. Wound cleansing, wound irrigation, wound disinfection. In: Krasner D, Kane D, editors. *Chronic wound care: A clinical source book for healthcare professionals*. Wayne, Pa: Health Management Publications; 1997. p. 97-108.
221. Williams D, Enoch S, Miller D, Harris K, Price P, Harding KG. Effect of sharp debridement using curette on recalcitrant nonhealing venous leg ulcers: A concurrently controlled, prospective cohort study. *Wound Repair Regen* 2005;13:131-7.
222. Cardinal M, Armstrong DG, Zelen C, Driver V, Attinger C, Phillips T, et al. Serial surgical debridement: A retrospective study on clinical outcomes in chronic lower extremity wounds. *Wound Repair Regen* 2009;17:306-11.
223. Blumberg SN, Maggi J, Melamed J, Golinko M, Ross F, Chen W. Histopathologic basis for surgical debridement to promote healing of venous leg ulcers. *J Am Coll Surg* 2012;215:751-7.
224. Sibbald RG, Williamson D, Orsted HL. Preparing the wound bed: Debridement, bacterial balance, and moisture balance. *Ostomy Wound Manage* 2000;46:14-35.
225. Bradley M, Cullum N, Sheldon T. The debridement of chronic wounds: A systematic review. *Health Technol Assess* 1999;3(Pt 1):1-78.
226. Briggs M, Nelson EA, Martyn-St James M. Topical agents or dressings for pain in venous leg ulcers. *Cochrane Database Syst Rev* 2012;11:CD001177.
227. Lok C, Paul C, Amblard P, Bessis D, Deburc C, Faivre B, et al. EMLA cream as a topical anesthetic for the repeated mechanical debridement of venous leg ulcers: A double-blind, placebo-controlled study. *J Am Acad Dermatol* 1999;40:208-13.
228. Hansson C, Holm J, Lillieborg S, Syren A. Repeated treatment with lidocaine/prilocaine cream (EMLA) as a topical anesthetic for the cleansing of venous leg ulcers. A controlled study. *Acta Derm Venereol* 1993;73:231-3.
229. Caputo WJ, Beggs DJ, DeFede JL, Simm L, Dharma H. A prospective randomized controlled clinical trial comparing hydro-surgery debridement with conventional surgical debridement in lower extremity ulcers. *Int Wound J* 2008;5:288-94.
230. Mosti G, Labichella ML, Picemi P, Magliaro A, Mattaliano V. The debridement of hard to heal leg ulcers by means of a new device based on Fluidjet technology. *Int Wound J* 2005;2:307-14.
231. Falanga V. Wound bed preparation and the role of enzymes: A case for multiple actions of the therapeutic agents. *Wounds* 2002;14:47-57.
232. Rao DB, Sane PG, Georgiev EL. Collagenase in the treatment of dermal and decubitus ulcers. *J Am Geriatr Soc* 1975;23:22-30.
233. Mosher BA, Cuddigan J, Thomas DR, Boudreau DM. Outcomes of 4 methods of debridement using a decision analysis methodology. *Adv Wound Care* 1999;12:81-8.
234. Dumville JC, Worthy G, Bland JM, Cullum N, Dowson C, Iglesias C, et al. Larval therapy for leg ulcers (VenUS II): Randomized controlled trial. *BMJ* 2009;338:773.
235. Soares MO, Iglesias CP, Bland JM, Cullum N, Dumville JC, Nelson EA, et al; VenUS II team. Cost-effectiveness analysis of larval therapy for leg ulcers. *BMJ* 2009;338:b825.
236. Dall L, Peterson S, Simmons T, Dall A. Rapid resolution of cellulitis in patients managed with combination antibiotic and anti-inflammatory therapy. *Cutis* 2005;75:177-80.
237. Khawcharoenporn T, Tice A. Empiric outpatient therapy with trimethoprim-sulfamethoxazole, cephalexin, or clindamycin for cellulitis. *Am J Med* 2010;123:942-50.
238. Madaras-Kelly KJ, Remington RE, Oliphant CM, Sloan KL, Bearden DT. Efficacy of oral beta-lactam versus non-beta-lactam treatment of uncomplicated cellulitis. *Am J Med* 2008;121:419-25.
239. Kilburn SA, Featherstone P, Higgins B, Brindle R. Interventions for cellulitis and erysipelas. *Cochrane Database Syst Rev* 2010;6:CD004299.
240. Sibbald RG, Contreras-Ruiz J, Coutts P, Fierheller M, Rothman A, Woo K. Bacteriology, inflammation, and healing: A study of nanocrystalline silver dressings in chronic venous leg ulcers. *Adv Skin Wound Care* 2007;20:549-58.
241. Lantis JC 2nd, Gendics C. In vivo effect of sustained-release silver sulphadiazine foam on bioburden and wound closure in infected venous leg ulcers. *J Wound Care* 2011;20:90-6.
242. Schraibman IG. The significance of beta-haemolytic streptococci in chronic leg ulcers. *Ann R Coll Surg Engl* 1990;72:123-4.
243. Manizgate F, Fuller A, Gendics C, Lantis JC 2nd. A prospective single-center, nonblinded, comparative, postmarket clinical evaluation of a bovine-derived collagen with ionic silver dressing versus a carboxymethylcellulose and ionic silver dressing for the reduction of bioburden in variable-etiology bilateral lower-extremity wounds. *Adv Skin Wound Care* 2012;25:220-5.
244. Vermeulen H, van Hattem JM, Storm-Versloot MN, Ubbink DT, Westerbos SJ. Topical silver for treating infected wounds. *Cochrane Database Syst Rev* 2007;1:CD005486.
245. Trengrove NJ, Stacey MC, MacAuley S, Bennett N, Gibson J, Burslem F, et al. Analysis of the acute and chronic wound environments: The role of proteases and their inhibitors. *Wound Rep Regen* 1999;7:442-52.

246. Yager DR, Zhang LY, Liang HX, Diegelmann RF, Cohen IK. Wound fluids from human pressure ulcers contain elevated matrix metalloproteinase levels and activity compared to surgical wound fluids. *J Invest Dermatol* 1996;107:743-8.
247. Michaels JA, Campbell B, King B, Palfreyman SJ, Shackley P, Stevenson M. Randomized controlled trial and cost-effectiveness analysis of silver-donating antimicrobial dressings for venous leg ulcers (VULCAN trial). *Br J Surg* 2009;96:1147-56.
248. Palfreyman S, Nelson EA, Michaels JA. Dressings for venous leg ulcers: Systematic review and meta-analysis. *BMJ* 2007;335:244.
249. O'Meara S, Al-Kurdi D, Ologun Y, Ovington LG. Antibiotics and antiseptics for venous leg ulcers. *Cochrane Database Syst Rev* 2010;1:CD003557.
250. Hess CT. Identifying and managing venous dermatitis. *Adv Skin Wound Care* 2005;18:242-3.
251. Kulozik M, Powell SM, Cherry G, Ryan TJ. Contact sensitivity in community-based leg ulcer patients. *Clin Exp Dermatol* 1988;13:82-4.
252. Tavadia S, Bianchi J, Dawe RS, McEvoy M, Wiggins E, Hamill E, et al. Allergic contact dermatitis in venous leg ulcer patients. *Contact Dermatitis* 2003;48:261-5.
253. Lal BK, Saito S, Pappas PJ, Padberg FT Jr, Cerveira JJ, Hobson RW 2nd, et al. Altered proliferative responses of dermal fibroblasts to TGF-beta1 may contribute to chronic venous stasis ulcer. *J Vasc Surg* 2003;37:1285-93.
254. Sadler GM, Wallace HJ, Stacy MC. Oral doxycycline for the treatment of chronic leg ulceration. *Arch Dermatol Res* 2012;304:487-93.
255. Jones JE, Nelson EA. Skin grafting for venous leg ulcers. *Cochrane Database Syst Rev* 2007;2:CD001737.
256. Serra R, Buffone G, de Francisicis A, Mastrangelo D, Vitagliano T, Greco M, et al. Skin grafting followed by low-molecular-weight heparin long-term therapy in chronic venous leg ulcers. *Ann Vasc Surg* 2012;26:190-7.
257. Warburg FE, Danielsen L, Madsen SM, Raaschou HO, Munkvad S, Jensen R, et al. Vein surgery with or without skin grafting versus conservative treatment for leg ulcers. A randomized prospective study. *Acta Derm Venereol* 1994;74:307-9.
258. Jankunas V. An analysis of the effectiveness of skin grafting to treat chronic venous leg ulcers. *Wounds* 2007;19:128-37.
259. Falanga V, Sabolinski M. A bilayered living skin construct (APLI-GRAF) accelerates complete closure of hard-to-heal venous ulcers. *Wound Repair Regen* 1999;7:201-7.
260. Falanga V, Margolis D, Alvarez O, Auletta M, Maggiasomo F, Altman M, et al. Rapid healing of venous ulcers and lack of clinical rejection with an allogeneic cultured human skin equivalent. Human Skin Equivalent Investigators Group. *Arch Dermatol* 1998;134:293-300.
261. Zaulyanov L, Kirsner RS. A review of a bi-layered living cell treatment (Apligraf) in the treatment of venous leg ulcers and diabetic foot ulcers. *Clin Interv Aging* 2007;2:93-8.
262. Hankin CS, Knispel J, Lopes M, Bronstone A, Maus E. Clinical and cost efficacy of advanced wound care matrices for venous ulcers. *J Manag Care Pharm* 2012;18:375-84.
263. Mostow EN, Araway GD, Dalsing M, Hodde JP, King D. Effectiveness of an extracellular matrix graft (OASIS Wound Matrix) in the treatment of chronic leg ulcers: A randomized clinical trial. *J Vasc Surg* 2005;41:837-43.
264. Vuerstaek JD, Vainas T, Wuite J, Nelemans P, Neumann MH, Veraart JC. State-of-the-art treatment of chronic leg ulcers: A randomized controlled trial comparing vacuum-assisted closure (V.A.C.) with modern wound dressings. *J Vasc Surg* 2006;44:1029-37; discussion: 1038.
265. Ubbink DT, Westerbos SJ, Evans D, Land L, Vermeulen H. Topical negative pressure for treating chronic wounds. *Cochrane Database Syst Rev* 2008;3:CD001898.
266. Houghton PE, Kincaid CB, Lovell M, Campbell KE, Keast DH, Woodbury MG, et al. Effect of electrical stimulation on chronic leg ulcer size and appearance. *Phys Ther* 2003;83:17-28.
267. Ennis WJ, Lee C, Plummer M, Meneses P. Current status of the use of modalities in wound care: Electrical stimulation and ultrasound therapy. *Plast Reconstr Surg* 2011;127(Suppl 1):93S-102S.
268. Gardner SE, Frantz RA, Schmidt FL. Effect of electrical stimulation on chronic wound healing: A meta-analysis. *Wound Repair Regen* 1999;7:495-503.
269. Driver VR, Fabbri M. Recent advances in the use of ultrasound in wound care. *Adv Wound Care* 2010;1:550-5.
270. Chuang LH, Soares MO, Watson JM, Bland JM, Cullum N, Iglesias C, et al. Economic evaluation of a randomized controlled trial of ultrasound therapy for hard-to-heal venous leg ulcers. *Br J Surg* 2011;98:1099-106.
271. Escandon J, Vivas AC, Perez R, Kirsner R, Davis S. A prospective pilot study of ultrasound therapy effectiveness in refractory venous leg ulcers. *Int Wound J* 2012;9:570-8.
272. Watson JM, Kang'ombe AR, Soares MO, Chuang LH, Worthy G, Bland JM, et al. Use of weekly, low dose, high frequency ultrasound for hard to heal venous leg ulcers: The VenUS III randomised controlled trial. *BMJ* 2011;342:d1092.
273. Cullum NA, Al-Kurdi D, Bell-Syer SE. Therapeutic ultrasound for venous leg ulcers. *Cochrane Database Syst Rev* 2010;6:CD001180.
274. Mosti G, Mattaliano V, Partsch H. Inelastic compression increases venous ejection fraction more than elastic bandages in patients with superficial venous reflux. *Phlebology* 2008;23:287-94.
275. Partsch H, Clark M, Mosti G, Steinlechner E, Schuren J, Abel M, et al. Classification of compression bandages: Practical aspects. *Dermatol Surg* 2008;34:600-9.
276. Partsch B, Partsch H. Calf compression pressure required to achieve venous closure from supine to standing positions. *J Vasc Surg* 2005;42:734-8.
277. Partsch H, Clark M, Bassez S, Benigni JP, Becker F, Blazek V, et al. Measurement of lower leg compression in vivo: Recommendations for the performance of measurements of interface pressure and stiffness: Consensus statement. *Dermatol Surg* 2006;32:224-32.
278. Rubin JR, Alexander J, Plecha EJ, Marman C. Unna's boot vs polyurethane foam dressings for the treatment of venous ulceration. A randomized prospective study. *Arch Surg* 1990;125:489-90.
279. O'Meara S, Cullum N, Nelson EA, Dumville JC. Compression for venous leg ulcers. *Cochrane Database Syst Rev* 2012;11:CD000265.
280. Eriksson G, Eklund A-E, Linden S, Zetterquist S. Comparison of different treatments of venous leg ulcers: A controlled study using stereophotogrammetry. *Curr Ther Res* 1984;35:678-84.
281. Taradaj J, Franek A, Dolibog P, Cierpka L, Blaszczak E. [The impact of the sonotherapy and compression therapy on enhancement of healing venous leg ulcers after surgical treatment]. *Pol Merkur Lekarski* 2007;23:426-9.
282. Kikta MJ, Schuler JJ, Meyer JP, Durham JR, Eldrup-Jorgensen J, Schwarcz TH, et al. A prospective, randomized trial of Unna's boots versus hydroactive dressing in the treatment of venous stasis ulcers. *J Vasc Surg* 1988;7:478-83.
283. Wong IK, Andriessen A, Charles HE, Thompson D, Lee DT, So WK, et al. Randomized controlled trial comparing treatment outcome of two compression bandaging systems and standard care without compression in patients with venous leg ulcers. *J Eur Acad Dermatol Venereol* 2012;26:102-10.
284. Charles H. Compression healing of ulcers. *J District Nurs* 1991;10:4-8.
285. Taylor A, Taylor RF, Marcuson RW. Prospective comparison of healing rates and therapy costs for conventional and four layer high compression bandaging treatments of venous leg ulcers. *Phlebology* 1998;13:20-4.
286. O'Brien JF, Grace PA, Perry IJ, Hannigan A, Clarke Moloney M, Burke PE. Randomized clinical trial and economic analysis of four-layer compression bandaging for venous ulcers. *Br J Surg* 2003;90:794-8.
287. Morrell CJ, Walters SJ, Dixon S, Collins KA, Brereton LM, Peters J, et al. Cost effectiveness of community leg ulcer clinics: Randomised controlled trial. *BMJ* 1998;316:1487-91.
288. Barwell JR, Davies CE, Deacon J, Harvey K, Minor J, Sassano A, et al. Comparison of surgery and compression alone in chronic venous ulceration (ESCHAR study): Randomised controlled trial. *Lancet* 2004;363:1854-9.

289. Nelson EA, Bell-Syer SE. Compression for preventing recurrence of venous ulcers. *Cochrane Database Syst Rev* 2012;8:CD002303.
290. Vandongen YK, Stacey MC. Graduated compression elastic stockings reduce lipodermatosclerosis and ulcer recurrence. *Phlebology* 2000;15:33-7.
291. Franks PJ, Oldroyd MI, Dickson D, Sharp EJ, Moffatt CJ. Risk factors for leg ulcer recurrence: A randomized trial of two types of compression stocking. *Age Ageing* 1995;24:490-4.
292. Mayberry JC, Moneta GL, Taylor LM Jr, Porter JM. Fifteen-year results of ambulatory compression therapy for chronic venous ulcers. *Surgery* 1991;109:575-81.
293. Nelson EA, Harper DR, Prescott RJ, Gibson B, Brown D, Ruckley CV. Prevention of recurrence of venous ulceration: Randomized controlled trial of class 2 and class 3 elastic compression. *J Vasc Surg* 2006;44:803-8.
294. Eriksson G. Comparison of two occlusive bandages in the treatment of venous leg ulcers. *Br J Dermatol* 1986;114:227-30.
295. Travers JP, Dalziel KL, Makin GS. Assessment of a new one-layer adhesive bandaging method in maintaining prolonged limb compression and effects on venous ulcer healing. *Phlebology* 1992;7:59-63.
296. Nelson EA, Prescott RJ, Harper DR, Gibson B, Brown D, Ruckley CV. A factorial, randomized trial of pentoxifylline or placebo, four-layer or single-layer compression, and knitted viscose or hydrocolloid dressings for venous ulcers. *J Vasc Surg* 2007;45:134-41.
297. O'Meara S, Tierney J, Cullum N, Bland JM, Franks PJ, Mole T, et al. Four layer bandage compared with short stretch bandage for venous leg ulcers: Systematic review and meta-analysis of randomised controlled trials with data from individual patients. *BMJ* 2009;338:b1344.
298. Partsch H, Damstra RJ, Tazelaar DJ, Schuller-Petrovic S, Velders AJ, de Rooij MJ, et al. Multicentre, randomised controlled trial of four-layer bandaging versus short-stretch bandaging in the treatment of venous leg ulcers. *Vasa* 2001;30:108-13.
299. Feben K. How effective is training in compression bandaging techniques? *Br J Community Nurs* 2003;8:80-4.
300. Wilkinson E, Buttfield S, Cooper S, Young E. Trial of two bandaging systems for chronic venous leg ulcers. *J Wound Care* 1997;6:339-40.
301. Vowden KR, Mason A, Wilkinson D, Vowden P. Comparison of the healing rates and complications of three four-layer bandage regimens. *J Wound Care* 2000;9:269-72.
302. Moffatt CJ, Simon DA, Franks PJ, Connolly M, Fielden S, Groarke L, et al. Randomised trial comparing two four-layer bandage systems in the management of chronic leg ulceration. *Phlebology* 1999;14:139-42.
303. Humphreys ML, Stewart AH, Gohel MS, Taylor M, Whyman MR, Poskitt KR. Management of mixed arterial and venous leg ulcers. *Br J Surg* 2007;94:1104-7.
304. Callam MJ, Ruckley CV, Dale JJ, Harper DR. Hazards of compression treatment of the leg: An estimate from Scottish surgeons. *Br Med J (Clin Res Ed)* 1987;295:1382.
305. Merrett ND, Hanel KC. Ischaemic complications of graduated compression stockings in the treatment of deep venous thrombosis. *Postgrad Med J* 1993;69:232-4.
306. Kay TW, Martin FI. Heel ulcers in patients with long-standing diabetes who wear antiembolism stockings. *Med J Aust* 1986;145:290-1.
307. Halperin MH, Friedland CK, Wilkins RW. The effect of local compression upon blood flow in the extremities of man. *Am Heart J* 1948;35:221-37.
308. Mayrovitz HN, Macdonald JM. Medical compression: Effects on pulsatile leg blood flow. *Int Angiol* 2010;29:436-41.
309. Mosti G, Iabichella ML, Partsch H. Compression therapy in mixed ulcers increases venous output and arterial perfusion. *J Vasc Surg* 2012;55:122-8.
310. Moffatt CJ, Oldroyd MI, Greenhalgh RM, Franks PJ. Palpating ankle pulses is insufficient in detecting arterial insufficiency in patients with leg ulceration. *Phlebology* 1994;9:170-2.
311. Marston WA, Carlin RE, Passman MA, Farber MA, Keagy BA. Healing rates and cost efficacy of outpatient compression treatment for leg ulcers associated with venous insufficiency. *J Vasc Surg* 1999;30:491-8.
312. Schuren J, Vos A, Allen JO. Venous leg ulcer patients with low ABPIs: How much pressure is safe and tolerable? *EWMA J* 2010;10:29-34.
313. McCulloch JM. Intermittent compression for the treatment of a chronic stasis ulceration: A case report. *Phys Ther* 1981;61:1452-3.
314. Pekanmaki K, Kolari PJ, Kiistala U. Intermittent pneumatic compression treatment for post-thrombotic leg ulcers. *Clin Exp Dermatol* 1987;12:350-3.
315. Nelson EA, Mani R, Thomas K, Vowden K. Intermittent pneumatic compression for treating venous leg ulcers. *Cochrane Database Syst Rev* 2011;2:CD001899.
316. Nikolovska S, Arsovski A, Damevska K, Gocev G, Pavlova L. Evaluation of two different intermittent pneumatic compression cycle settings in the healing of venous ulcers: A randomized trial. *Med Sci Monit* 2005;11:CR337-43.
317. van Gent WB, Hop WC, van Praag MC, Mackaay AJ, de Boer EM, Wittens CH. Conservative versus surgical treatment of venous leg ulcers: A prospective, randomized, multicenter trial. *J Vasc Surg* 2006;44:563-71.
318. Gohel MS, Barwell JR, Taylor M, Chant T, Foy C, Earnshaw JJ, et al. Long term results of compression therapy alone versus compression plus surgery in chronic venous ulceration (ESCHAR): Randomised controlled trial. *BMJ* 2007;335:83.
319. Lin Y, Ye CS, Huang XL, Ye JL, Yin HH, Wang SM. A random comparative study on endovenous laser therapy and saphenous veins stripping for the treatment of great saphenous vein incompetence. *Zhonghua Yi Xue Za Zhi* 2007;87:3043-6.
320. Theivacumar NS, Darwood R, Gough MJ. Neovascularization and recurrence 2 years after treatment for sapheno-femoral and great saphenous reflux: A comparison of surgery and endovenous laser. *Eur J Vasc Endovasc Surg* 2009;38:203-7.
321. Christenson JT, Gueddi S, Gemayel G, Bounameaux H. Prospective randomized trial comparing endovenous laser ablation and surgery for treatment of primary great saphenous varicose veins with a 2-year follow-up. *J Vasc Surg* 2010;52:1234-41.
322. Pronk P, Gauw SA, Mooij, Gaastra MT, Lawson JA, van Goethem AR, et al. Randomised controlled trial comparing sapheno-femoral ligation and stripping of the great saphenous vein with endovenous laser ablation (980 nm) using local tumescent anaesthesia: One year results. *Eur J Vasc Endovasc Surg* 2010;40:649-56.
323. Carradice D, Mekako AI, Mazari FA, Samuel N, Hatfield J, Chetter IC. Clinical and technical outcomes from a randomised clinical trial of endovenous laser ablation with conventional surgery for great saphenous varicose veins. *Br J Surg* 2011;98:1117-23.
324. Rass K, Frings N, Glowacki P, Hamsch C, Gräber S, Vogt T, et al. Comparable effectiveness of endovenous laser ablation and high ligation with stripping of the great saphenous vein: Two-year results of a randomized clinical trial (RELACS study). *Arch Dermatol* 2012;148:49-58.
325. Rasmussen L, Lawaetz M, Bjoern L, Blemings A, Eklöf B. Randomized trial comparing endovenous laser ablation and stripping of the great saphenous vein with duplex outcome after 5 years. *J Vasc Surg* 2013;58:421-6.
326. Lurie F, Creton D, Eklöf B, Kabnick LS, Kistner RL, Pichot O, et al. Prospective randomized study of endovenous radiofrequency obliteration (Closure) versus ligation and vein stripping (EVOLVEs). Two year follow-up. *Eur J Vasc Endovasc Surg* 2005;29:67-73.
327. Perala J, Rautio T, Biancari F, Ohtonen P, Wiik H, Heikkinen T, et al. Radiofrequency endovenous obliteration versus stripping of the long saphenous vein in the management of primary varicose veins: 3-year outcome of a randomized study. *Ann Vasc Surg* 2005;19:1-4.
328. Kianifard B, Holdstock JM, Whiteley MS. Radiofrequency ablation (VNUS Closure) does not cause neo-vascularization at the groin at one year: Results of a case controlled study. *Surgeon* 2006;4:71-4.
329. Stötter L, Schaaf I, Bockelbrink A. Comparative outcomes of radiofrequency endoluminal ablation, invagination stripping and cryostripping in the treatment of great saphenous vein. *Phlebology* 2006;21:60-4.
330. Helmy ElKaffas K, ElKashef O, ElBaz W. Great saphenous vein radiofrequency ablation versus standard stripping in the management of primary varicose veins—a randomized clinical trial. *Angiology* 2010;62:49-54.

331. O'Hare JL, Earnshaw JJ. Randomised clinical trial of foam sclerotherapy for patients with a venous leg ulcer. *Eur J Vasc Endovasc Surg* 2010;39:495-9.
332. Eklöf B, Perrin M. Randomised controlled trials comparing endovenous thermal and chemical ablation. In: Greenhalgh R, editor. *Vascular and endovascular challenges update*. London: BIBA Publishing; 2013. p. 402-8.
333. Lakhwani MN, Dadlani NI, Wong YC. 980-nm laser therapy versus varicose vein surgery in racially diverse Penang, Malaysia. *ANZ J Surg* 2009;79:352-7.
334. Zamboni P, Cisno C, Marchetti F, Mazza P, Fogato L, Carandina S, et al. Minimally invasive surgical management of primary venous ulcers vs. compression treatment: A randomized clinical trial. *Eur J Vasc Endovasc Surg* 2003;25:313-8.
335. Howard DP, Howard A, Kothari A, Wales L, Guest M, Davies AH. The role of superficial venous surgery in the management of venous ulcers: A systematic review. *Eur J Vasc Endovasc Surg* 2008;36:458-65.
336. Neglén P. Prevention and treatment of venous ulcers in primary chronic venous insufficiency. *J Vasc Surg* 2010;52(Suppl):15S-20S.
337. Harlander-Locke M, Lawrence PF, Alktaifi A, Jimenez JC, Rigberg D, DeRubertis B. The impact of ablation of incompetent superficial and perforator veins on ulcer healing rates. *J Vasc Surg* 2012;55:458-64.
338. Viarengo LMA, Poterio-Filho J, Poterio GMB, Menezes FH, Meirelles GV. Endovenous laser treatment for varicose veins in patients with active ulcers: Measurement of intravenous and perivenous temperatures during the procedure. *Dermatol Surg* 2007;33:1234-41.
339. Gloviczki P, Bergan JJ, Menawat SS, Hobson RW 2nd, Kistner RL, Lawrence PF, et al. Safety, feasibility, and early efficacy of subfascial endoscopic perforator surgery: A preliminary report from the North American registry. *J Vasc Surg* 1997;25:94-105.
340. Tenbrook JA Jr, Iafrafi MD, O'Donnell TF Jr, Wolf MP, Hoffinan SN, Pauker SG, et al. Systematic review of outcomes after surgical management of venous disease incorporating subfascial endoscopic perforator surgery. *J Vasc Surg* 2004;39:583-93.
341. Masuda FM, Kessler DM, Lurie F, Puggioni A, Kistner RL, Eklof B. The effect of ultrasound-guided sclerotherapy of incompetent perforating veins on venous clinical severity and disability scores. *J Vasc Surg* 2006;43:551-7.
342. Kinanifard B, Holdstock J, Allen C, Smith C, Price B, Whiteley MS. Randomized clinical trial of the effect of adding subfascial endoscopic perforator surgery to standard great saphenous vein stripping. *Br J Surg* 2007;94:1075-80.
343. Proebstle TM, Herdemann S. Early results and feasibility of incompetent perforator vein ablation by endovenous laser treatment. *Dermatol Surg* 2007;33:162-8.
344. Elias S, Peden E. Ultrasound-guided percutaneous ablation for the treatment of perforating vein incompetence. *Vascular* 2007;15:281-9.
345. Luebke T, Brunkwall J. Meta-analysis of subfascial endoscopic perforator vein surgery (SEPS) for chronic venous insufficiency. *Phlebology* 2009;24:8-16.
346. Bacon JL, Dinneen AJ, Marsh P, Holdstock JM, Price BA, Whiteley MS. Five-year results of incompetent perforator vein closure using TRans-Luminal Occlusion of Perforator. *Phlebology* 2009;24:74-8.
347. O'Donnell TF. The role of perforators in chronic venous insufficiency. *Phlebology* 2010;25:3-10.
348. Harlander-Locke M, Lawrence P, Jimenez JC, Rigberg D, DeRubertis B, Gelabert H. Combined treatment with compression therapy and ablation of incompetent superficial and perforating veins reduces ulcer recurrence in patients with CEAP 5 venous disease. *J Vasc Surg* 2012;55:446-50.
349. Lawrence PF, Alktaifi A, Rigberg D, DeRubertis B, Gelabert H, Jimenez JC. Endovenous ablation of incompetent perforating veins is effective treatment for recalcitrant venous ulcers. *J Vasc Surg* 2011;54:737-42.
350. Pierik EG, van Urk H, Hop WC, Wittens CH. Endoscopic versus open subfascial division of incompetent perforating veins in the treatment of venous leg ulceration: A randomized trial. *J Vasc Surg* 1997;26:1049-54.
351. Nelzen O. Prospective study of safety, patient satisfaction and leg ulcer healing following saphenous and subfascial endoscopic perforator surgery. *Br J Surg* 2000;87:86-91.
352. Iafrafi MD, Pare GJ, O'Donnell TF, Estes J. Is the nihilistic approach to surgical reduction of superficial and perforator vein incompetence for venous ulcer justified? *J Vasc Surg* 2002;36:1167-74.
353. Van Gent W, Wittens C. Influence of perforating vein surgery in patients with venous ulceration. *Phlebology* 2013. Dec 19 [Epub ahead of print].
354. Gloviczki P, Bergan JJ, Rhodes JM, Canton LG, Harmsen S, Ilstrup DM. Mid-term results of endoscopic perforator vein interruption for chronic venous insufficiency: Lessons learned from the North American Subfascial Endoscopic Perforator Surgery registry. *J Vasc Surg* 1999;29:489-502.
355. Vranic H, Hadzimehmedagic A, Mirsad KM, Mirza D, Adnana T. Combined compressive-surgical treatment of chronic venous ulcer of the leg. *HealthMed* 2010;4:890-5.
356. Bush R, Bush P. Percutaneous foam sclerotherapy for venous leg ulcers. *J Wound Care* 2013;22(Suppl):S20-2.
357. Rueda CA, Bittenbinder EN, Buckley CJ, Bohannon WT, Atkins MD, Bush RL. The management of chronic venous insufficiency with ulceration: The role of minimally invasive perforator interruption. *Ann Vasc Surg* 2013;27:89-95.
358. Bush RG. New technique to heal venous ulcers: Terminal interruption of the reflux source (TIRS). *Perspect Vasc Surg Endovasc Ther* 2010;22:194-9.
359. O'Donnell TF, Mackey WC, Shepard AD, Callow AD. Clinical, hemodynamic, and anatomic follow-up of direct venous reconstruction. *Arch Surg* 1987;122:474-82.
360. Bry JD, Muto PA, O'Donnell TF, Isaacson LA. The clinical and hemodynamic results after axillary-to-popliteal vein valve transplantation. *J Vasc Surg* 1995;21:110-9.
361. Raju S. Venous insufficiency of the lower limb and stasis ulceration: Changing concepts and management. *Ann Surg* 1983;197:688-97.
362. Raju S, Fredericks R. Valve reconstruction procedures for non-obstructive venous insufficiency: Rationale, techniques, and results in 107 procedures with two- to eight-year follow-up. *J Vasc Surg* 1988;7:301-10.
363. Perrin MR. Results of deep-vein reconstruction. *Vasc Surg* 1997;31:273-5.
364. Taheri SA, Lazar L, Elias SM, Marchand P. Vein valve transplant. *Surgery* 1982;91:28-33.
365. Taheri SA, Elias SM, Yacobucci GN, Hefner R, Lazar L. Indications and results of vein valve transplant. *J Cardiovasc Surg (Torino)* 1986;27:163-8.
366. Nash T. Long-term results of vein valve transplants placed in the popliteal vein for intractable post-phlebotic venous ulcers and pre-ulcer skin changes. *J Cardiovasc Surg (Torino)* 1988;29:712-6.
367. Rai DB, Lerner R. Chronic venous insufficiency disease: Its etiology: A new technique for vein valve transplantation. *Int Surg* 1991;76:174-8.
368. Sottuirai VS. Results of deep-vein reconstruction. *Vasc Surg* 1997;31:276-8.
369. Eklof BG, Kistner RL, Masuda EM. Venous bypass and valve reconstruction: Long-term efficacy. *Vasc Med* 1998;3:157-64.
370. Puggioni A, Kistner RL, Eklof B, Lurie F. Surgical disobliteration of postthrombotic deep veins—endophlebectomy—is feasible. *J Vasc Surg* 2004;39:1048-52.
371. Gloviczki P, Cho JS. Surgical treatment of chronic occlusions of the iliac veins and the inferior vena cava. In: Rutherford RB, editor. *Vascular surgery*. 6th ed. Philadelphia: Saunders Elsevier; 2005. p. 2303-20.
372. Vogel D, Comerota AJ, Al Jabouri M, Assi Z. Common femoral endovenectomy with ilioacaval endoluminal recanalization improves symptoms and quality of life in patients with postthrombotic iliofemoral obstruction. *J Vasc Surg* 2012;55:129-35.
373. Garg N, Gloviczki P, Karimi KM, Duncan AA, Bjarnason H, Kalra M, et al. Factors affecting outcome of open and hybrid reconstructions

- for nonmalignant obstruction of iliofemoral veins and inferior vena cava. *J Vasc Surg* 2011;53:383-93.
374. Linton RR, Hardy JB. Postthrombotic syndrome of the lower extremity. Treatment by interruption of the superficial femoral vein and ligation and stripping of the long and short saphenous veins. *Surgery* 1948;24:452-68.
 375. Eriksson I, Almgren MD. Influence of the profunda femoris vein on venous hemodynamics of the limb. Experience from thirty-one deep vein valve reconstructions. *J Vasc Surg* 1986;4:390-5.
 376. Masuda EM, Kistner RL, Ferris EB. Long-term effects of superficial femoral vein ligation: Thirteen-year follow-up. *J Vasc Surg* 1992;16:741-9.
 377. Tripathi R, Sicunarine K, Abbas M, Durrani N. Deep venous reconstruction for non-healing leg ulcers: Techniques and results. *ANZ J Surg* 2004;74:34-9.
 378. Raju S, Fredericks RK, Neglen PN, Bass JD. Durability of venous valve reconstruction techniques for "primary" and post-thrombotic reflux. *J Vasc Surg* 1996;23:357-67.
 379. Lane JL, Cuzzilla ML, McMahon DG. Intermediate to long-term results of repairing incompetent multiple deep venous valves using external valvular stenting. *ANZ J Surg* 2003;73:267-74.
 380. Guarnera G, Furgiuele S, Mascellari L, Bianchini G, Camilli S. External banding of the superficial femoral vein in the treatment of recurrent varicose veins. *Int Angiol* 1998;17:268-71.
 381. Makhatilov G, Askerkhanov G, Kazakmurzaev MA, Ismailov I. Endoscopically directed external support of femoral vein valves. *J Vasc Surg* 2009;49:676-80.
 382. Raju S, Berry MA, Neglen P. Transcommissural valvuloplasty: Technique and results. *J Vasc Surg* 2000;32:969-76.
 383. Raju S, Hardy JD. Technical options in venous valve reconstruction. *Am J Surg* 1997;173:301-7.
 384. Nishibe T, Kudo F, Flores J, Miyazaki K, Yasuda K. Femoral vein valve repair with angiography-assisted anterior valve sinus plication. Early results. *J Cardiovasc Surg (Torino)* 2001;42:529-35.
 385. Kistner RL. Surgical technique of external venous valve repair. *Straub Found Proc* 1990;55:15.
 386. Nishibe T, Kudo F, Miyazaki K, Kondo Y, Koizumi J, Dardik A, et al. Intermediate-term results of angiography-assisted anterior valve sinus plication for primary deep venous insufficiency. *J Cardiovasc Surg (Torino)* 2007;48:21-5.
 387. Glociczki P, Merrell SW, Bower TC. Femoral vein valve repair under direct vision without venotomy: A modified technique with use of angiography. *J Vasc Surg* 1991;14:645-8.
 388. Belcaro G, Nicolaidis AN, Ricci A, Laurora G, Errichi BM, Christopoulos D, et al. External femoral vein valvuloplasty with limited anterior plication (LAP): A 10-year randomized, follow-up study. *Angiology* 1999;50:531-6.
 389. Wang S, Hu Z, Li S, Huang XL, Ye CS. Effect of external valvuloplasty of the deep vein in the treatment of chronic venous insufficiency of the lower extremity. *J Vasc Surg* 2006;44:1296-300.
 390. Us M, Basaran M, Sanioglu S, Ogun NT, Ozbek C, Yildirim T, et al. The use of external banding increases the durability of transcommissural external deep venous valve repair. *Eur J Vasc Endovasc Surg* 2007;33:494-550.
 391. Ferris EB, Kistner RL. Femoral vein reconstruction in the management of chronic venous insufficiency: A 14-year experience. *Arch Surg* 1982;117:1571-9.
 392. Eriksson I. Reconstructive surgery for deep vein valve incompetence in the lower limb. *Eur J Vasc Surg* 1990;4:211-8.
 393. Cheatle TR, Perrin M. Venous valve repair: Early results in fifty-two cases. *J Vasc Surg* 1994;19:404-13.
 394. Masuda EM, Kistner RL. Long-term results of venous valve reconstruction: A four to twenty-one year follow-up. *J Vasc Surg* 1994;19:391-403.
 395. Perrin M. Reconstructive surgery for deep venous reflux: A report on 144 cases. *Cardiovasc Surg* 2000;8:246-55.
 396. Tripathi R, Ktenidis KD. Trapdoor internal valvuloplasty: A new technique for primary deep vein valvular incompetence. *Eur J Vasc Endovasc Surg* 2001;22:86-9.
 397. Perrin M, Hiltbrand B, Bayon JM. Results of valvuloplasty in patients presenting deep venous insufficiency and recurring ulceration. *Ann Vasc Surg* 1999;13:524-32.
 398. Kistner RL. Surgical repair of the incompetent femoral vein valve. *Arch Surg* 1975;110:1336-42.
 399. Lurie F, Makarova NP, Hmelniker SM. Results of deep-vein reconstruction. *Vasc Surg* 1997;31:275-6.
 400. Johnson ND, Queral LA, Flinn WR, Yao JS, Bergan JJ. Late objective assessment of venous valve surgery. *Arch Surg* 1981;116:146-66.
 401. Sotturrai VS. Current surgical approaches to venous hypertension and valvular reflux. *Int J Angiol* 1996;5:49-54.
 402. Cardon JM, Cardon A, Joyeux A, Mangialardi N, Noblet D, Nguyen T, et al. Use of ipsilateral greater saphenous vein as a valved transplant in management of post-thrombotic deep venous insufficiency: Long-term results. *Ann Vasc Surg* 1999;13:284-9.
 403. Lehtola A, Oinonen A, Sugano N, Albäck A, Lepäntalo M. Deep venous reconstructions: Long-term outcome in patients with primary or post-thrombotic deep venous incompetence. *Eur J Vasc Endovasc Surg* 2008;35:487-93.
 404. Queral LA, Whitehouse WM Jr, Flinn WR, Neiman HL, Yao JS, Bergan JJ. Surgical correction of chronic deep venous insufficiency by valvular transposition. *Surgery* 1980;87:688-95.
 405. Iafrai M, O'Donnell TF. Surgical reconstruction for deep venous insufficiency. *J Mal Vasc* 1997;22:193-7.
 406. Raju S, Neglen P, Doolittle J, Meydrech EF. Axillary vein transfer in trabeculated postthrombotic veins. *J Vasc Surg* 1999;29:1050-64.
 407. Opie JC, Payne DN, Opie SR. Monocusp—novel common femoral vein monocusp surgery uncorrectable chronic venous insufficiency with aplastic/dysplastic valves. *Phlebology* 2008;23:158-71.
 408. Ignat'ev IM, Akhmetzianov RV, Bredikhin RA. First experience in forming a multi-flap valve of the common femoral vein in a valvuloplasty of the deep veins of lower extremities. *Angiol Sosud Khir* 2010;16:77-9.
 409. Lugli M, Guerzoni S, Garofalo M, Smedile G, Maleti O. Neovalve construction in deep venous incompetence. *J Vasc Surg* 2009;49:156-63.
 410. Maleti O, Perrin M. Reconstructive surgery for deep vein reflux in the lower limbs: Techniques, results and indications. *Eur J Vasc Surg* 2011;41:837-48.
 411. Neglen P, Thrasher TL, Raju S. Venous outflow obstruction: An underestimated contributor to chronic venous disease. *J Vasc Surg* 2003;38:879-85.
 412. Labropoulos N, Volteas N, Leon M, Sowade O, Rulo A, Giannoukas AD, et al. The role of venous outflow obstruction in patients with chronic venous dysfunction. *Arch Surg* 1997;132:46-51.
 413. Hartung O, Loundou AD, Barthelemy P, Amoux D, Boufi M, Alimi YS. Endovascular management of chronic disabling ilio-caval obstructive lesions: Long-term results. *Eur J Vasc Endovasc Surg* 2009;38:118-24.
 414. Meng QY, Li XQ, Qian AM, Sang HF, Rong JJ, Zhu LW. Endovascular treatment of iliac vein compression syndrome. *Chin Med J (Engl)* 2011;124:3281-4.
 415. Neglen P, Hollis KC, Olivier J, Raju S. Stenting of the venous outflow in chronic venous disease: Long-term stent-related outcome, clinical, and hemodynamic result. *J Vasc Surg* 2007;46:979-90.
 416. Ye K, Lu X, Li W, Huang Y, Huang X, Lu M, et al. Long-term outcomes of stent placement for symptomatic nonthrombotic iliac vein compression lesions in chronic venous disease. *J Vasc Interv Radiol* 2012;23:497-502.
 417. Raju S, Neglen P. Percutaneous recanalization of total occlusions of the iliac vein. *J Vasc Surg* 2009;50:360-8.
 418. Rosales A, Sandback G, Jorgensen JJ. Stenting for chronic post-thrombotic vena cava and iliofemoral venous occlusions: mid-term patency and clinical outcome. *Eur J Vasc Endovasc* 2010;40:234-40.
 419. Raju S. Best management options for chronic iliac vein stenosis and occlusion. *J Vasc Surg* 2013;57:1163-9.
 420. Kolbel T, Lindh M, Akesson M, Wasselius J, Gottsater A, Ivancev K. Chronic iliac vein occlusion: Midterm results of endovascular recanalization. *J Endovasc Therapy* 2009;16:483-91.

421. Alhalbouni S, Hingorani A, Shiferson A, Gopal K, Jung D, Novak D, et al. Iliac-femoral venous stenting for lower extremity venous stasis symptoms. *Ann Vasc Surg* 2012;26:185-9.
422. Gutzeit A, ChL Zollikofer, Dettling-Pizzolato M, Graf N, Largiader J, Binkert CA. Endovascular stent treatment for symptomatic benign iliofemoral venous occlusive disease: Long-term results 1987-2009. *Cardiovasc Intervent Radiol* 2011;34:542-9.
423. Hurst DR, Forauer AR, Bloom JR, Greenfield LJ, Wakefield TW, Williams DM. Diagnosis and endovascular treatment of ilioacaval compression syndrome. *J Vasc Surg* 2001;34:106-13.
424. Juhan C, Hartung O, Alimi Y, Barthelemy P, Valerio N, Portier F. Treatment of nonmalignant obstructive ilioacaval lesions by stent placement: Mid-term results. *Ann Vasc Surg* 2001;15:227-32.
425. Kurklsinsky AK, Bjarnason H, Friese JL, Wysokinski WE, McBane RD, Misselt A, et al. Outcomes of venoplasty with stent placement for chronic thrombosis of the iliac and femoral veins: Single-center experience. *J Vasc Interv Radiol* 2012;23:1009-15.
426. Oguzkurt L, Tercan F, Ozkan U, Gulcan O. Iliac vein compression syndrome: Outcome of endovascular treatment with long-term follow-up. *Eur J Radiol* 2008;68:487-92.
427. O'Sullivan GJ, Semba CP, Bittner CA, Kee ST, Razavi MK, Sze DY, et al. Endovascular management of iliac vein compression (May-Thurner) syndrome. *J Vasc Interv Radiol* 2000;11:823-36.
428. Neglen P, Tackett TP Jr, Raju S. Venous stenting across the inguinal ligament. *J Vasc Surg* 2008;48:1255-61.
429. Danza R, Navarro T, Baldizan J. Reconstructive surgery in chronic venous obstruction of the lower limbs. *J Cardiovasc Surg (Torino)* 1991;32:98-103.
430. Gloviczki P, Pailorero PC, Toomey BJ, Bower TC, Rooke TW, Stanson AW, et al. Reconstruction of large veins for nonmalignant venous occlusive disease. *J Vasc Surg* 1992;16:750-61.
431. Jost CJ, Gloviczki P, Cherry KJ Jr, McKusick MA, Harmsen WS, Jenkins GD, et al. Surgical reconstruction of iliofemoral veins and the inferior vena cava for nonmalignant occlusive disease. *J Vasc Surg* 2001;33:320-7; discussion: 327-8.
432. Lalka SG, Unthank JL, Last HM, McGue JF, Cikrit DF, Sawchuk AP, et al. Hemodynamic effects of varied graft diameters in the venous system. *Surgery* 1991;110:73-9.
433. Lalka SG, Lash JM, Unthank JL, Lalka VK, Cikrit DF, Sawchuk AP, et al. Inadequacy of saphenous vein grafts for cross-femoral venous bypass. *J Vasc Surg* 1991;13:622-30.
434. Halliday P, Harris J, May JJE. Femoro-femoral crossover grafts (Palma operation): A long-term follow-up study. In: Bergan JJ, Yao JST, editors. *Surgery of the veins*. Orlando, Fla: Grune & Stratton; 1985. p. 241-54.
435. Harris JP, Kidd J, Burnett A, Halliday P, May J. Patency of femoro-femoral venous crossover grafts assessed by duplex scanning and phlebography. *J Vasc Surg* 1988;8:679-82.
436. Danza R, Nav Raju S. New approaches to the diagnosis and treatment of venous obstruction. *J Vasc Surg* 1986;4:42-54.
437. Dalsing MC, Lalka SG, Zukowski AJ, Unthank JL, Sawchuk AP, Cikrit DF. Valve transplantation to the canine popliteal vein: The utility of a distal arteriovenous fistula and the hemodynamic result of a single functional valve. *J Vasc Surg* 1994;20:736-43.
438. Edwards WS. A-V fistula after venous reconstruction. A simplified method of producing and obliterating the shunt. *Ann Surg* 1982;196:669-71.
439. Eklof B. Arteriovenous fistulas as an adjunct to venous surgery. *Semin Vasc Surg* 2000;13:20-6.
440. Plate G, Akesson H, Einarsson E, Ohlin P, Eklof B. Long-term results of venous thrombectomy combined with a temporary arterio-venous fistula. *Eur J Vasc Surg* 1990;4:483-9.
441. Gwilt M, Athis J. Treating venous leg ulceration with complementary therapy. *Community Nurse* 2000;6:51-3.
442. Clarke-Moloney M, Lyons GM, Burke PE, O'Keefe D, Grace PA. A review of technological approaches to venous ulceration. *Crit Rev Biomed Eng* 2005;33:511-56.
443. Heinen MM, van Achterberg T, op Reimer WS, van de Kerkhof PC, de Laat E. Venous leg ulcer patients: A review of the literature on lifestyle and pain-related interventions. *J Clin Nurs* 2004;13:355-66.
444. Robson MC, Cooper DM, Aslam R, Gould LJ, Harding KG, Margolis DJ, et al. Guidelines for the treatment of venous ulcers. *Wound Repair Regen* 2006;14:649-62.
445. Cullum N, Nelson EA, Flemming K, Sheldon T. Systematic reviews of wound care management: (5) beds; (6) compression; (7) laser therapy, therapeutic ultrasound, electrotherapy and electromagnetic therapy. *Health Technol Assess* 2001;5:1-221.
446. Ramelet AA. Controversies on emerging and obsolete therapies in venous leg ulcers. *Curr Probl Dermatol* 1999;27:161-4.
447. Phillips TJ. Successful methods of treating leg ulcers. The tried and true, plus the novel and new. *Postgrad Med* 1999;105:159-61, 165-6, 173-4 passim.
448. Bello YM, Phillips TJ. Management of venous ulcers. *J Cutan Med Surg* 1998;3(Suppl 1):S1-6-12.
449. Marston WA, Farber MA, Bryant J, Burns J, Keagy BA. Management of lower extremity venous stasis ulcers in a comprehensive wound care clinic. *N C Med J* 1998;59:128-31.
450. Wissing UE, Wengstrom Y, Skold G, Unosson M. Can individualized nutritional support improve healing in therapy-resistant leg ulcers? *J Wound Care* 2002;11:15-20.
451. Pompeo M. Misconceptions about protein requirements for wound healing: Results of a prospective study. *Ostomy Wound Manage* 2007;53:30.
452. Rojas AI, Phillips TJ. Patients with chronic leg ulcers show diminished levels of vitamins A and E, carotenes, and zinc. *Dermatol Surg* 1999;25:601-4.
453. Legendre C, Debure C, Meaume S, Lok C, Golmard JL, Senet P. Impact of protein deficiency on venous ulcer healing. *J Vasc Surg* 2008;48:688-93.
454. Wipke-Tevis DD, Stotts NA. Nutrition, tissue oxygenation, and healing of venous leg ulcers. *J Vasc Nurs* 1998;16:48-56.
455. Coleridge Smith PD, editor. *Drug treatment of varicose veins, venous edema, and ulcers*. London: Hodder Arnold; 2009.
456. Greaves MW, Skillen AW. Effects of long-continued ingestion of zinc sulphate in patients with venous leg ulceration. *Lancet* 1970;2:889-91.
457. Wilkinson EA, Hawke CI. Does oral zinc aid the healing of chronic leg ulcers? A systematic literature review. *Arch Dermatol* 1998;134:1556-60.
458. Browse NL, Burnand KG. The cause of venous ulceration. *Lancet* 1982;2:243-5.
459. Layer GT, Stacey MC, Burnand KG. Stanozolol and the treatment of venous ulceration: An interim report. *Phlebology* 1986;1:197-203.
460. Browse NL, Jarrett PE, Morland M, Burnand K. Treatment of liposclerosis of the leg by fibrinolytic enhancement: A preliminary report. *Br Med J* 1977;2:434-5.
461. Coccheri S, Scodotto G, Agnelli G, Aloisi D, Palazzini E, Zamboni V. Randomised, double blind, multicentre, placebo controlled study of sulodexide in the treatment of venous leg ulcers. *Thromb Haemost* 2002;87:947-52.
462. Layton AM, Ibbotson SH, Davies JA, Goodfield MJ. Randomised trial of oral aspirin for chronic venous leg ulcers. *Lancet* 1994;344:164-5.
463. Lyon RT, Veith FJ, Bolton L, Machado F. Clinical benchmark for healing of chronic venous ulcers. *Venous Ulcer Study Collaborators*. *Am J Surg* 1998;176:172-5.
464. Beitner H, Hammar H, Olsson AG, Thyresson N. Prostaglandin E₁ treatment of leg ulcers caused by venous or arterial incompetence. *Acta Derm Venereol* 1980;60:425-30.
465. Rudofsky G. Intravenous prostaglandin E₁ in the treatment of venous ulcers—a double-blind, placebo-controlled trial. *Vasa Suppl* 1989;28:39-43.
466. Milio G, Mina C, Cospite V, Almasio PL, Novo S. Efficacy of the treatment with prostaglandin E-1 in venous ulcers of the lower limbs. *J Vasc Surg* 2005;42:304-8.
467. Coleridge Smith PD, Thomas P, Scurr JH, Dormandy JA. Causes of venous ulceration: A new hypothesis. *Br Med J (Clin Res Ed)* 1988;296:1726-7.
468. Lyseng-Williamson KA, Perry CM. Micronised purified flavonoid fraction: A review of its use in chronic venous insufficiency, venous ulcers and haemorrhoids. *Drugs* 2003;63:71-100.
469. Guillhou JJ, Dereure O, Marzin L, Ouvry P, Zuccarelli F, Debure C, et al. Efficacy of Daflon 500 mg in venous leg ulcer

- healing: A double-blind, randomized, controlled versus placebo trial in 107 patients. *Angiology* 1997;48:77-85.
470. Coleridge-Smith P, Lok C, Ramelet AA. Venous leg ulcer: A meta-analysis of adjunctive therapy with micronized purified flavonoid fraction. *Eur J Vasc Endovasc Surg* 2005;30:198-208.
 471. Guillhou JJ, Fevrier F, Debure C, Dubeaux D, Gillet-Terver MN, Guillot B, et al. Benefit of a 2-month treatment with a micronized, purified flavonoid fraction on venous ulcer healing. A randomized, double-blind, controlled versus placebo trial. *Int J Microcirc Clin Exp* 1997;17(Suppl 1):21-6.
 472. Gliniski W, Chodyncka B, Roszkiewicz J, et al. [Effectiveness of a micronized purified flavonoid fraction (MPFF) in the healing process of lower limb ulcers. An open multicentre study, controlled and randomized]. *Minerva Cardioangiol* 2001;49:107-14.
 473. Smith PC. Daflon 500 mg and venous leg ulcer: New results from a meta-analysis. *Angiology* 2005;56(Suppl 1):S33-9.
 474. Gohel MS, Davies AH. Pharmacological treatment in patients with C4, C5 and C6 venous disease. *Phlebology* 2010;25(Suppl 1):35-41.
 475. Katsenis K. Micronized purified flavonoid fraction (MPFF): A review of its pharmacological effects, therapeutic efficacy and benefits in the management of chronic venous insufficiency. *Curr Vasc Pharmacol* 2005;3:1-9.
 476. Coleridge Smith PD. From skin disorders to venous leg ulcers: Pathophysiology and efficacy of Daflon 500 mg in ulcer healing. *Angiology* 2003;54(Suppl 1):S45-50.
 477. Jull A, Arroll B, Parag V, Waters J. Pentoxifylline for treating venous leg ulcers. *Cochrane Database Syst Rev* 2007;3:CD001733.
 478. Jull A, Waters J, Arroll B. Pentoxifylline for treatment of venous leg ulcers: A systematic review. *Lancet* 2002;359:1550-4.
 479. De Sanctis MT, Belcaro G, Cesarone MR, Ippolito E, Nicolaides AN, Incandela L, et al. Treatment of venous ulcers with pentoxifylline: A 12-month, double-blind, placebo controlled trial. *Microcirculation and healing*. *Angiology* 2002;53(Suppl 1):S49-51.
 480. Falanga V, Fujitani RM, Diaz C, Hunter G, Jorizzo J, Lawrence PF, et al. Systemic treatment of venous leg ulcers with high doses of pentoxifylline: Efficacy in a randomized, placebo-controlled trial. *Wound Repair Regen* 1999;7:208-13.
 481. Dale JJ, Ruckley CV, Harper DR, Gibson B, Nelson EA, Prescott RJ. Randomised, double blind placebo controlled trial of pentoxifylline in the treatment of venous leg ulcers. *BMJ* 1999;319:875-8.
 482. Mirshahi S, Soria J, Mirshahi M, et al. Expression of elastase and fibrin in venous leg ulcer biopsies: A pilot study of pentoxifylline versus placebo. *J Cardiovasc Pharmacol* 1995;25(Suppl 2):S101-5.
 483. Iglesias CP, Claxton K. Comprehensive decision-analytic model and Bayesian value-of-information analysis: Pentoxifylline in the treatment of chronic venous leg ulcers. *Pharmacoeconomics* 2006;24:465-78.
 484. Sullivan GW, Carper HT, Novick WJ Jr, Mandell GL. Inhibition of the inflammatory action of interleukin-1 and tumor necrosis factor (alpha) on neutrophil function by pentoxifylline. *Infect Immun* 1988;56:1722-9.
 485. Heinen MM, Evers AW, Van Uden CJ, Van der Vleuten CJ, van de Kerkhof PC, Van Achterberg T. Sedentary patients with venous or mixed leg ulcers: Determinants of physical activity. *J Adv Nurs* 2007;60:50-7.
 486. Heinen MM, van der Vleuten C, de Rooij MJ, Uden CJ, Evers AW, van Achterberg T. Physical activity and adherence to compression therapy in patients with venous leg ulcers. *Arch Dermatol* 2007;143:1283-8.
 487. Roaldsen KS, Rollman O, Torebjork E, Olsson E, Stanghelle JK. Functional ability in female leg ulcer patients—a challenge for physiotherapy. *Physiother Res Int* 2006;11:191-203.
 488. Brown A. Life-style advice and self-care strategies for venous leg ulcer patients: What is the evidence? *J Wound Care* 2012;21:342-4, 346, 348-50.
 489. Kelechi TJ, Green A, Dumas B, Brotherton SS. Online coaching for a lower limb physical activity program for individuals at home with a history of venous ulcers. *Home Healthc Nurse* 2010;28:596-605.
 490. Jull A, Parag V, Walker N, Maddison R, Kerse N, Johns T. The prepare pilot RCT of home-based progressive resistance exercises for venous leg ulcers. *J Wound Care* 2009;18:497-503.
 491. Davies JA, Bull RH, Farrelly IJ, Wakelin MJ. A home-based exercise programme improves ankle range of motion in long-term venous ulcer patients. *Phlebology* 2007;22:86-9.
 492. Padberg FT Jr, Johnston MV, Sisto SA. Structured exercise improves calf muscle pump function in chronic venous insufficiency: A randomized trial. *J Vasc Surg* 2004;39:79-87.
 493. Kan YM, Delis KT. Hemodynamic effects of supervised calf muscle exercise in patients with venous leg ulceration: A prospective controlled study. *Arch Surg* 2001;136:1364-9.
 494. Klysz T, Junger M, Rassner G. Physical therapy of the ankle joint in patients with chronic venous incompetence and arthrogenic congestive syndrome. *Curr Probl Dermatol* 1999;27:141-7.
 495. Stahel HU. Manual lymph drainage. *Curr Probl Dermatol* 1999;27:148-52.
 496. Pereira de Godoy JM, Braile DM, de Fatima Guerreiro Godoy M. Lymph drainage in patients with joint immobility due to chronic ulcerated lesions. *Phlebology* 2008;23:32-4.
 497. Carpentier PH, Blaise S, Satger B. A multicenter randomized controlled trial evaluating balneotherapy in patients with advanced chronic venous insufficiency. *J Vasc Surg* 2014;59:447-54.
 498. Ippolito E, De Luca S, Sommaruga S, Grassellino V, Nappi G. Experimental-clinical study on the effects of hydromassage with Thermae Oasis's salsobromiodine water in chronic venous stasis disease of the lower extremities. *Minerva Cardioangiol* 2008;56:401-8.
 499. Ernst E, Saradeth T, Resch KL. A single blind randomized, controlled trial of hydrotherapy for varicose veins. *Vasa* 1991;20:147-52.
 500. Dodd HJ, Sarkany I, Gaylarde PM. The short-term benefit and long-term failure of ultraviolet light in the treatment of venous leg ulcers. *Br J Dermatol* 1989;120:809-18.
 501. Rabe E, Hertel S, Bock E, Hoffmann B, Jockel KH, Pannier F. Therapy with compression stockings in Germany—results from the Bonn Vein Studies. *J Dtsch Dermatol Ges* 2013;11:257-61.
 502. Criqui MH, Jamosmos M, Fronck A, Denenberg JO, Langer RD, Bergan J, et al. Chronic venous disease in an ethnically diverse population: The San Diego Population Study. *Am J Epidemiol* 2003;158:448-56.
 503. Labropoulos N, Leon L, Kwon S, Tassiopoulos A, Gonzalez-Fajardo JA, Kang SS, et al. Study of the venous reflux progression. *J Vasc Surg* 2005;41:291-5.
 504. Vogeley CL, Coeling H. Prevention of venous ulceration by use of compression after deep vein thrombosis. *J Vasc Nurs* 2000;18:123-7.
 505. Araki CT, Back TL, Padberg FT, Thompson PN, Jamil Z, Lee BC, et al. The significance of calf muscle pump function in venous ulceration. *J Vasc Surg* 1994;20:872-7; discussion: 878-9.
 506. Zajkowski PJ, Proctor MC, Wakefield TW, Bloom J, Blessing B, Greenfield LJ. Compression stockings and venous function. *Arch Surg* 2002;137:1064-8.
 507. Ibegbuna V, Delis KT, Nicolaides AN, Aina O. Effect of elastic compression stockings on venous hemodynamics during walking. *J Vasc Surg* 2003;37:420-5.
 508. Amsler F, Blattler W. Compression therapy for occupational leg symptoms and chronic venous disorders—a meta-analysis of randomized controlled trials. *Eur J Vasc Endovasc Surg* 2008;35:366-72.
 509. Mosti G, Partsch H. Compression stockings with a negative pressure gradient have a more pronounced effect on venous pumping function than graduated elastic compression stockings. *Eur J Vasc Endovasc Surg* 2011;42:261-6.
 510. Mosti G, Partsch H. High compression pressure over the calf is more effective than graduated compression in enhancing venous pump function. *Eur J Vasc Endovasc Surg* 2012;44:332-6.
 511. Motykie GD, Caprini JA, Arcelus JI, Reyna JJ, Overom E, Mokhtee D. Evaluation of therapeutic compression stockings in the treatment of chronic venous insufficiency. *Dermatol Surg* 1999;25:116-20.
 512. Korn P, Patel ST, Heller JA, Deitch JS, Krishnasastri KV, Bush HL, et al. Why insurers should reimburse for compression stockings in patients with chronic venous stasis. *J Vasc Surg* 2002;35:950-7.
 513. Berard A, Abenheim L, Platt R, Kahn SR, Steinmetz O. Risk factors for the first-time development of venous ulcers of the lower limbs: The influence of heredity and physical activity. *Angiology* 2002;53:647-57.

514. Welkie JF, Comerota AJ, Katz ML, Aldridge SC, Kerr RP, White JV. Hemodynamic deterioration in chronic venous disease. *J Vasc Surg* 1992;16:733-40.
515. Maurins U, Hoffmann BH, Losch C, Jockel KH, Rabe E, Pannier F. Distribution and prevalence of reflux in the superficial and deep venous system in the general population—results from the Bonn Vein Study, Germany. *J Vasc Surg* 2008;48:680-7.
516. Haenen JH, Janssen MC, Wollersheim H, Van't Hof MA, de Rooij MJ, van Langen H, et al. The development of postthrombotic syndrome in relationship to venous reflux and calf muscle pump dysfunction at 2 years after the onset of deep venous thrombosis. *J Vasc Surg* 2002;35:1184-9.
517. Aschwanden M, Jeanneret C, Koller MT, Thalhammer C, Bucher HC, Jaeger KA. Effect of prolonged treatment with compression stockings to prevent post-thrombotic sequelae: A randomized controlled trial. *J Vasc Surg* 2008;47:1015-21.
518. Prandoni P, Lensing AW, Prins MH, Frulla M, Marchiori A, Bernardi E, et al. Below-knee elastic compression stockings to prevent the post-thrombotic syndrome: A randomized, controlled trial. *Ann Intern Med* 2004;141:249-56.
519. Ginsberg JS, Hirsh J, Julian J, Vander LaandeVries M, Magier D, MacKinnon B, et al. Prevention and treatment of postphlebotic syndrome: Results of a 3-part study. *Arch Intern Med* 2001;161:2105-9.
520. Roumen-Klappe EM, den Heijer M, van Rossum J, Wollersheim H, van der Vleuten C, Thien T, et al. Multilayer compression bandaging in the acute phase of deep-vein thrombosis has no effect on the development of the post-thrombotic syndrome. *J Thromb Thrombolysis* 2009;27:400-5.
521. Kakkos SK, Daskalopoulou SS, Daskalopoulos ME, Nicolaidis AN, Geroulakos G. Review on the value of graduated elastic compression stockings after deep vein thrombosis. *Thromb Haemost* 2006;96:441-5.
522. Kearon C, Akl EA, Comerota AJ, Prandoni P, Bounameaux H, Goldhaber SZ, et al. Antithrombotic therapy for VTE disease: Antithrombotic Therapy and Prevention of Thrombosis, 9th ed: American College of Chest Physicians Evidence-Based Clinical Practice Guidelines. *Chest* 2012;141:e419S-94S.
523. Kahn SR, Shapiro S, Wells PS, Rodger MA, Kovacs MJ, Anderson DR. SOX trial investigators. Compression stockings to prevent post-thrombotic syndrome: A randomised placebo-controlled trial. *Lancet* 2014;383:880-8.
524. Ginsberg JS, Magier D, Mackinnon B, Gent M, Hirsh J. Intermittent compression units for severe post-phlebotic syndrome: A randomized crossover study. *CMAJ* 1999;160:1303-6.
525. O'Donnell MJ, McRae S, Kahn SR, Julian JA, Kearon C, Mackinnon B, et al. Evaluation of a venous-return assist device to treat severe post-thrombotic syndrome (VENOPTS). A randomized controlled trial. *Thromb Haemost* 2008;99:623-9.
526. Comerota AJ. Intermittent pneumatic compression: Physiologic and clinical basis to improve management of venous leg ulcers. *J Vasc Surg* 2011;53:1121-9.
527. Berliner E, Ozbilgin B, Zarin DA. A systematic review of pneumatic compression for treatment of chronic venous insufficiency and venous ulcers. *J Vasc Surg* 2003;37:539-44.
528. Tsai S, Dubovoy A, Wainess R, Upchurch GR Jr, Wakefield TW, Henke PK. Severe chronic venous insufficiency: Magnitude of the problem and consequences. *Ann Vasc Surg* 2005;19:705-11.
529. Kahn SR, Ginsberg JS. Relationship between deep venous thrombosis and the postthrombotic syndrome. *Arch Intern Med* 2004;164:17-26.
530. Kahn SR, Shrier I, Julian JA, Ducruet T, Arsenault L, Miron MJ, et al. Determinants and time course of the postthrombotic syndrome after acute deep venous thrombosis. *Ann Intern Med* 2008;149:698-707.
531. Arpaia G, Cimminiello C, Mastrogiacomo O, de Gaudenzi E. Efficacy of elastic compression stockings used early or after resolution of the edema on recanalization after deep venous thrombosis: The COM-PRE trial. *Blood Coagul Fibrinolysis* 2007;18:131-7.
532. Partsch H. Ambulation and compression after deep vein thrombosis: Dispelling myths. *Semin Vasc Surg* 2005;18:148-52.
533. Weitz JI, Eikelboom JW, Samama MM. New antithrombotic drugs: Antithrombotic Therapy and Prevention of Thrombosis, 9th ed: American College of Chest Physicians Evidence-Based Clinical Practice Guidelines. *Chest* 2012;141:e120S-51S.
534. Becattini C, Agnelli G, Schenone A, Eichinger S, Bucherini E, Silingardi M. WARFASA Investigators. Aspirin for preventing the recurrence of venous thromboembolism. *N Engl J Med* 2012;366:1959-67.
535. Hull RD, Pineo GF, Brant R, Liang J, Cook R, Solymoss S, et al. Home therapy of venous thrombosis with long-term LMWH versus usual care: Patient satisfaction and post-thrombotic syndrome. *Am J Med* 2009;122:762-9.e3.
536. Hull RD, Liang J, Townshend G. Long-term low-molecular-weight heparin and the post-thrombotic syndrome: A systematic review. *Am J Med* 2011;124:756-65.
537. Palareti G, Cosmi B, Legnani C, Tosetto A, Brusi C, Iorio A, et al. D-dimer testing to determine the duration of anticoagulation therapy. *N Engl J Med* 2006;355:1780-9.
538. Siragusa S, Malato A, Saccullo G, Iorio A, Di Ianni M, Caracciolo C, et al. Residual vein thrombosis for assessing duration of anticoagulation after unprovoked deep vein thrombosis of the lower limbs: The extended DACUS study. *Am J Hematol* 2011;86:914-7.
539. Carrier M, Rodger MA, Wells PS, Righini M, Le Gal G. Residual vein obstruction to predict the risk of recurrent venous thromboembolism in patients with deep vein thrombosis: A systematic review and meta-analysis. *J Thromb Haemost* 2011;9:1119-25.
540. Eenden T, Haig Y, Klow NE, Slagsvold CE, Sandvik L, Ghanima W, et al. Long-term outcome after additional catheter-directed thrombolysis versus standard treatment for acute iliofemoral deep vein thrombosis (the CaVenT study): A randomised controlled trial. *Lancet* 2012;379:31-8.
541. Popuri RK, Vedantham S. The role of thrombolysis in the clinical management of deep vein thrombosis. *Arterioscler Thromb Vasc Biol* 2011;31:479-84.
542. Abu-Own A, Scurr JH, Coleridge Smith PD. Effect of leg elevation on the skin microcirculation in chronic venous insufficiency. *J Vasc Surg* 1994;20:705-10.
543. Yang D, Vandongen YK, Stacey MC. Effect of exercise on calf muscle pump function in patients with chronic venous disease. *Br J Surg* 1999;86:338-41.
544. Frykberg RG, Zgonis T, Armstrong DG, Driver VR, Giurini JM, Kravitz SR, et al. Diabetic foot disorders. A clinical practice guideline (2006 revision). *J Foot Ankle Surg* 2006;45:S1-66.
545. Poterio-Filho J, Silveira SA, Poterio GM, Fecuri RJ, de Almeida FH, Menezes FH. The effect of walking with high-heeled shoes on the leg venous pressure. *Angiology* 2006;57:424-30.
546. Tedeschi Filho W, Dezzotti NR, Joviliano EE, Moriya T, Piccinato CE. Influence of high-heeled shoes on venous function in young women. *J Vasc Surg* 2012;56:1039-44.
547. Saggini R, Bellomo RG, Iodice P, Lessiani G. Venous insufficiency and foot dysmorphism: Effectiveness of visco-elastic rehabilitation systems on veno-muscle system of the foot and of the calf. *Int J Immunopathol Pharmacol* 2009;22:1-8.